

# Acalculous Cholecystitis or Biliary Dyskinesia for Epstein-Barr Virus Gallbladder Involvement?

**Andrew Fretzayas, Maria Moustaki, Achilleas Attilakos, Triantafillia Brozou, Polyxeni Nicolaidou**

3<sup>rd</sup> Department of Pediatrics, Faculty of Medicine, University of Athens, Athens, Greece

Received December 13, 2013; Accepted April 4, 2014.

**Key words:** EBV – Cholecystitis – Biliary dyskinesia

**Abstract:** We present two patients with Epstein-Barr virus (EBV) infection related to gallbladder involvement. Such an association is already known as EBV induced acalculous cholecystitis, diagnosed on the basis of ultrasonographic findings. In our patients, radioisotopic cholescintigraphy was also performed and it showed that gallbladder was visualized in both patients in contrast to that what can be observed in cases of cholecystitis. However, the value of ejection fraction was compatible with biliary dyskinesia. We, therefore, consider that impaired gallbladder contractility in EBV infection cases may actually represent biliary dyskinesia and not acalculous cholecystitis taking into account the radioisotopic findings and the self limited course of the disorder.

**Mailing Address:** Andrew Fretzayas, MD., PhD., 3<sup>rd</sup> Department of Pediatrics, “Attikon” University Hospital, Faculty of Medicine, University of Athens, 1 Rimini str., Haidari, 12462 Athens, Greece; Phone: 003 021 058 322 28; Fax: 003 021 058 322 29; e-mail: mar.moustaki@gmail.com

## Introduction

Epstein-Barr virus (EBV) infectious mononucleosis is a well known entity in young children and adolescents running, as a rule, an indolent course. The EBV apart from its lymphotropism exhibits considerable hepatotropism, a predilection proclaimed by increased liver enzymes or true cholestasis. Involvement of the extrahepatic biliary outflow tract is rather an infrequent manifestation numbering less than twenty cases in the literature (Arya et al., 2010).

We, herein, describe two children with acute infectious mononucleosis who presented symptoms, laboratory indices and imaging findings suggestive of acute cholecystitis. Interpreting the data from dynamic cholescintigraphic studies, in acute and convalescent state, we provide evidence that EBV related gallbladder involvement may represent transient dyskinesia, taking into consideration the benign and transient course of this manifestation as well as the visualization of the gallbladder by <sup>99</sup>Tc hydroxy-iminodiacetic acid (HIDA).

## Patient 1

An 11-year-old young girl, with non contributory past medical history, was admitted to the Department of Pediatrics with eyelid oedema of ten days duration followed by a two day history of high spiking fever. Physical examination revealed petechiae on the palate, hyperemic pharynx with marked tonsillar enlargement, few palpable cervical anterior, posterior and submandibular lymph nodes and hepatosplenomegaly (liver 2 cm, spleen 3 cm).

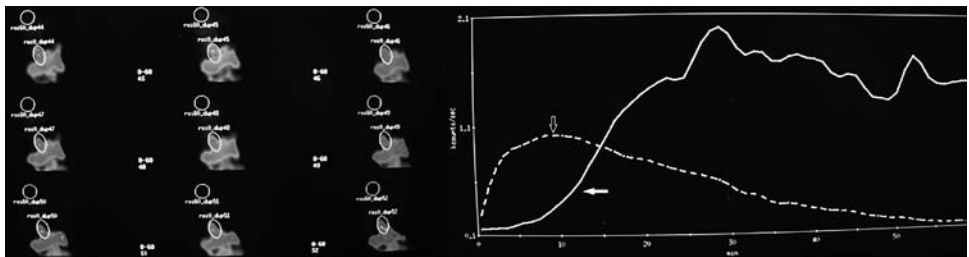
The laboratory investigation showed: Hb 13.9 g/dl, Ht 41.3%, white blood cells 14.680/mm<sup>3</sup> with concomitant lymphocytosis (70%) and monocytosis (15%), CRP 5 mg/l and ESR 8 mm/h. Liver function tests showed aspartate aminotransferase 291 U/l, alanine aminotransferase 198 U/l, alkaline phosphatase 536 U/l, gamma-glutamyl transpeptidase 52 U/l, total bilirubin 30.78 μmol/l with a direct component 6.84 μmol/l. Because of mild unconjugated hyperbilirubinemia the promoter region [A (TA)<sub>6</sub> TAA] of the UGT1A1 gene was examined with molecular techniques and the patient was found to carry the UGT1A1\* 28 mutation in heterozygous state.

The clinical presentation, along with the laboratory findings, led us to investigate a possible contribution of viral hepatotropic agents. Antibodies for hepatitis C, CMV and Herpes simplex virus were all negative. *Toxoplasma gondii* and leptospirosis were also excluded with the appropriate tests. However, heterophil antibodies, as detected by the monospot test, were positive. Antibodies to EBV nuclear antigen (EBNA) were negative, whereas IgM antibodies to EBV viral capsid antigen (VCA) were positive with IgG antibodies to EBV viral capsid antigen being negative. Abdominal ultrasound revealed only enlarged liver and spleen.

Two days later, the fever was remitted but the patient complained about abdominal pain, mainly at the palpation of the right upper quadrant of the abdomen with a positive Murphy sign. The ultrasound examination was repeated and at that

time it showed an image consistent with the diagnosis of acalculous cholecystitis i.e. manifestation of thickened oedematous gallbladder wall (7.3 mm) without dilation of the biliary tract. A radioisotopic cholangiography was then performed, using 185 MBq  $^{99m}\text{Tc}$ -bromo-2,4,6-trimethylacetanilido iminodiacetic acid (BRIDA) as a tracer. A prompt uptake of the radioisotopic agent from the hepatic cells was noticed and the passage from the liver to the gallbladder and its filling were established as anticipated. However, emptying of gallbladder was not accomplished even after the administration of a fatty meal and ejection fraction was negligible at 45 min (Figure 1 – Panel A). A repeated ultrasonographic examination, ten days later, revealed normal thickness of the gallbladder wall and no other findings consistent with gallbladder inflammation and negative sonographic Murphy's sign. A cholescintigraphic examination of the gallbladder, following an identical to the initial protocol, was performed one month later. It was noted, prompt uptake of the radiotracer by the liver with normal filling of the gallbladder and liver to duodenum transit time within the normal limits. Motility of the gallbladder has been considerably improved since the initial examination with an ejection fraction calculated to  $> 70\%$ , although emptying was not fully accomplished at the end of the study at 60 minutes (Figure 1 – Panel B).

Panel A



Panel B

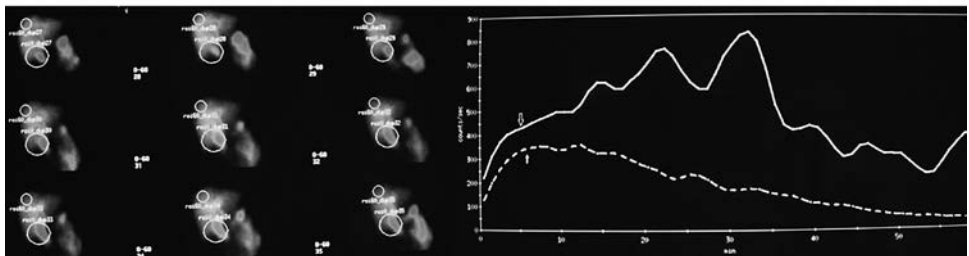


Figure 1 – Representative scintigraphic images taken one month apart (Panel A and Panel B) following IV administration of 185 MBq  $^{99m}\text{Tc}$ -BRIDA.

Panel A: Prompt and intense uptake of the radiotracer by the liver and in time excretion to the biliary tract. The tracer was accumulated in the gallbladder for the next 45 min. Following the administration of a standard fatty meal a zero ejection fraction was calculated (arrowhead: liver activity curve, arrow: gallbladder activity curve).

Panel B (one month later): The gallbladder ejection fraction was normalized after the administration of a standard fatty meal (arrow: liver activity curve, arrowhead: gallbladder activity curve).

## Patient 2

A 12-year-old girl was examined at the emergency pediatrics department with a history of fever as high as 38.5 °C which lasted for three consecutive days and thereafter she remained afebrile for two days. However, she had developed coryza, cough and mild abdominal pain the last twelve hours prior to the examination with reoccurrence of high temperature (38.4 °C). On physical examination liver and spleen were both palpable below the respective costal margins and the eyelids were mildly oedematous, whereas thrombocytopenia was shown in the full blood count. On admission to the Department of Pediatrics, hematological investigation revealed the following: Hb 12.1 g/dl, Ht 36.6%, white blood cells 4900/mm<sup>3</sup>, neutrophils 38%, monocytes 9% and lymphocytes 53%, platelets 109000/mm<sup>3</sup>, CRP 11 mg/l. With the exception of elevated aminotransferases and gamma-glutamyl transpeptidase (aspartate aminotransferase 134 U/l, alanine aminotransferase 125 U/l, gamma-glutamyl transpeptidase 162 U/l) the remaining biochemical indices were within the normal range. Antibodies to hepatotropic agents did not reveal IgM or IgG antibodies to hepatitis C, CMV, Toxoplasma and cytomegalovirus, whereas IgM antibodies to EBV viral capsid antigen (VCA) were positive with IgG antibodies to EBV viral capsid antigen being negative. An abdominal ultrasound was also performed because of the hepatosplenomegaly, which revealed liver and spleen with normal echogenicity. The gallbladder, however, had thickened oedematous wall of 9 mm with recognizable striation and there was sludge in the gallbladder. Because of these findings a radioisotopic cholangiography was then performed, using 185 MBq 99mTc-BRIDA as a tracer. The radiotracer was normally uptaken by the liver and choledochal cyst filling was also normal. However, there was a delay of the gallbladder emptying between the 70<sup>th</sup> and the 180<sup>th</sup> min, after the administration of a fatty meal.

The patient remained febrile for 6 days at the hospital. Platelets returned to normal values (193000/mm<sup>3</sup>) the 5<sup>th</sup> day of admission. She was discharged afebrile, on the 8<sup>th</sup> day and at the follow up 30 days later, aminotransferases and gamma-glutamyl transpeptidase concentrations were within the normal range as well as the thickness of the gallbladder wall appreciated with sonography. Wall striation or sludge was not apparent at this repeated ultrasound. As it was expected, at the follow up she developed IgG antibodies to EBV viral capsid antigen.

## Discussion

So far, in all reported cases of EBV infection with gallbladder involvement, researchers have coined unanimously the term “acute acalculous cholecystitis” (AAC) to enclose in the same entity the clinical symptoms and the ultrasonographic findings (Arya et al., 2010). Imaging modalities, especially ultrasonography and cholescintigraphy, have been considered the most reliable method for the diagnosis of AAC. Among sonographic findings, increased thickness of the gallbladder wall ( $\geq 3\text{--}5$  mm), recognizable striation, pericholecystic fluid,

presence of sludge and a positive sonographic Murphy's sign have been considered diagnostic (Smith et al., 2009).

However, we should keep in mind that the term AAC is a consequence of various other disorders, accounting for 2–15% of all cases of acute cholecystitis (Middleton and Williams, 2001) (severe burns, sustained trauma, sepsis, parenteral alimentation, major surgery, immunosuppression, etc.). AAC usually runs a severe course necessitating intervention and it may be followed by complications in contrast to the benign and transient nature of gallbladder involvement in EBV infection.

In cases of EBV induced gallbladder involvement, the term was based on ultrasonographic morphological findings (Arya et al., 2010). To the best of our knowledge, this is the first time that radioisotopic cholescintigraphy is performed in an attempt to recognize potential deviation of gallbladder functional parameters. The ejection fraction in the initial study of the first patient was zero indicating that there was substantial biliary dyskinesia, as a normal gallbladder ejection fraction has been defined as greater than 35% (Middleton and Williams, 2001). More importantly, the gallbladder was fulfilled, while it has been recognized that in cases of acute cholecystitis the filling is abolished due to the cystic duct obstruction from an entrapped stone or from a deteriorating inflammatory process (Kalimi et al., 2001).

In the second patient the delay of gallbladder emptying was suggestive of mild biliary dyskinesia whereas its filling was normal, putting therefore in doubt the diagnosis of acute cholecystitis given that sensitivity of non visualization of gallbladder in cases of cholecystitis is estimated to be high (Kalimi et al., 2001).

A question that also arises for the first patient is whether heterozygosis  $TA_6/TA_7$  for *UDPGT1* promoter contributed to the specific clinical manifestations of EBV infection. Such a possibility cannot be ruled out, based on the experience of Guala et al. (2003) who showed a more severe clinical course of infectious mononucleosis with liver involvement as a consequence of this genetic feature.

Considering the transient nature and the favourable outcome of the reported cases of EBV related and so-called AAC, which is not the case for AAC of other etiology, powered by scintigraphic findings in our cases, we challenge the appropriateness of the coined term for EBV AAC. To be correct regarding the terminology, dyskinesia (a word of Greek origin which indicates “compromised movement”) which means that the function of gallbladder emptying is impaired whereas the filling process works properly seems to us more appropriate. Presumably the background for the development of dyskinesia is the inflammation of the gallbladder wall. However, based on the scintigraphic findings the inflammation is not severe enough and as a consequence the gallbladder fulfilling is normal whereas the emptying is impaired and the clinical course of the disease is self-limited. Therefore the term acute acalculous cholecystitis may be to some extent exaggerated and therefore misleading.

## References

- Arya, S. O., Saini, A., El-Baba, M., Salimnia, H., Abdel-Haq, N. (2010) Epstein Barr virus-associated acute acalculous cholecystitis: a rare occurrence but favorable outcome. *Clin. Pediatr. (Phila.)* **49**, 799–804.
- Guala, A., Campa, D., Marinelli, I., Gaidano, G., Pagani, L. (2003) Are Gilbert's syndrome and liver involvement genetically linked in infectious mononucleosis? *Pediatr. Infect. Dis. J.* **22**, 1110–1111.
- Kalimi, R., Gecelter, G. R., Caplin, D., Brickman, M., Tronco, G. T., Love, C., Yao, J., Simms, H. H., Marini, C. P. (2001) Diagnosis of acute cholecystitis: sensitivity of sonography, cholescintigraphy, and combined sonography-cholescintigraphy. *J. Am. Coll. Surg.* **193**, 609–613.
- Middleton, G. W., Williams, J. H. (2001) Diagnostic accuracy of <sup>99</sup>Tcm-HIDA with cholecystokinin and gallbladder ejection fraction in acalculous gallbladder disease. *Nucl. Med. Commun.* **22**, 657–661.
- Smith, E. A., Dillman, J. R., Elsayes, K. M., Menias, C. O., Bude, R. O. (2009) Cross-sectional imaging of acute and chronic gallbladder inflammatory disease. *AJR Am. J. Roentgenol.* **192**, 188–196.