

# Fournier's Gangrene in a Patient with Obesity and B-lymphoma

**Komninos C., Karavitakis M., Koritsiadis S.**

Department of Urology, General Hospital Nikaia – Piraeus “Saint Panteleimon”, Piraeus, Greece

Received May 7, 2013; Accepted August 14, 2013.

**Key words:** Fournier's gangrene – Necrotizing fasciitis – Obese – Lymphoma

**Abstract:** We present a case of Fournier's gangrene disease in a young obese patient with coexistent B-lymphoma. It remains controversial if obesity constitutes a predisposing factor for an individual to develop necrotizing fasciitis. On the other hand, only few cases of patients with coexistence of B-lymphoma and Fournier's gangrene disease have been reported. A 30-years-old obese man was admitted to emergency department with fever (38.7 °C), pain, erythema and swelling extended from the left scrotum to the left lower abdominal quadrant. He was confused, with low urinary excretion and septic shock's signs. The clinical findings were characteristics of Fournier's gangrene disease. Furthermore during physical examination a massive, painless and motionless mass in the left breast was revealed. The patient required urgent surgical debridement of the affected area and pus drainage. Biopsies of the breast mass were received by excision. Pus and blood cultures yielded *Staphylococci* coagulase(-), *Klebsiella* and *Proteus* sp. Intravenous antibiotic treatment with Meropeneme and Clindamycine started immediately. Repeated debridement was often performed. Pathology examination of the massive tissue revealed a diffuse B-lymphoma of large cells (Germinal center B-cell like-GCB). The patient was discharged from the hospital 35 days later. Afterwards, he was treated with chemotherapeutic agents for malignant lymphoma at the oncological department. The aim of this case's presentation is to mention that young obese patients with Fournier's gangrene disease should be particularly investigated due to the possible occurrence of another not obvious predisposing factor, such as a malignant disease.

**Mailing Address:** Christos Komninos, MD., MSc., Department of Urology, General Hospital Nikaia – Piraeus “Saint Panteleimon”, 3 D, Mantouvalou St., 18454, Piraeus, Greece; Phone: +302 132 077 205; e-mail: chrkom@yahoo.gr

## Introduction

Fournier's gangrene is a rare soft-tissue polymicrobial infection characterized by rapidly spreading inflammation and subsequent necrosis of the muscle fascia, subcutaneous fat and in some cases the epidermis. It is usually located in the scrotum, the penis and it can be expanded in the perineum and the abdomen. In 1883, Jean-Alfred Fournier described and named the disease, although the condition had been described earlier (Fournier, 1883). In 1952, Wilson used the term necrotizing fasciitis to describe the gangrene which extend in the abdomen (Wilson, 1952). In practice, necrotizing fasciitis and Fournier's gangrene are equal terms. Fournier's gangrene usually develops after trauma, endoscopic injury, infections of the urogenital system or microbe's extension from the colon, the anus and the rectum (Sorensen et al., 2009). Diabetes mellitus and immunosuppression constitute significant etiological factors. Obesity and B-lymphoma have rarely been correlated as predisposing factors (Yumura et al., 2000). We present a case of Fournier's gangrene disease in a young obese patient with coexistent B-lymphoma.

## Case report

A 30-years-old obese man (BMI = 56 kg/m<sup>2</sup>) was admitted to emergency department with fever (38.7 °C), pain, erythema and swelling extended from the left scrotum to the left lower abdominal quadrant. The symptoms started within 24 hours. He did not refer any trauma, endoscopic handling or any other predisposing factors related to Fournier's gangrene, such as diabetes mellitus. During physical examination body temperature was 38.7 °C, respiratory frequency was 35 b/min, heart rate was 120 beats/min, arterial pressure was 80/50 mm Hg (mean arterial pressure 60 mm Hg) and the patient was confused with low urinary excretion. Physical examination of the left scrotum and the abdomen revealed sensitivity, redness and swelling. Digital rectum examination was normal. Moreover, a massive, painless and motionless mass in the left breast was revealed. Laboratory findings showed polynucleosis (WBC: 21.2 K/ $\mu$ l), creatinine: 3.9 mg/dl, CRP:



Figure 1 – Ultrasound showed great scrotal tunicae thickening stratification and gas within the scrotal wall.

390 mg/l, LDH: 1,550 IU/l, glucose: 120 mg/dl, while arterial blood gas sampling showed lactic acidosis. Urine examination and chest radiograph were normal. The ultrasound showed great scrotal tunicae thickening, stratification and gas within the scrotal wall (Figure 1). Testes were normal.

The clinical and image findings were characteristics of Fournier's gangrene disease. The infection extended from the left scrotum to the Scarpa's fascia in the left abdomen wall, condition which caused severe sepsis. The patient required urgent surgical debridement of the affected area, excision of necrotic tissue and pus drainage (Figure 2). The breast mass was totally excised and the tissue was sent for pathological examination. Intravenous crystalloids fluids and antibiotic treatment with Meropeneme and Clindamycine started immediately, while pus and blood cultures yielded *Staphylococci coagulase(-)*, *Klebsiella* and *Proteus* sp. sensitive in the antibiotic treatment. Repeated debridement was often performed. Sequential irrigation using povidone iodine liquid, oxyzene and normal saline were effective. Clinical and laboratory findings were improved within 48 hours. Pathology examination of the massive tissue revealed a high grade, diffuse B-lymphoma of large cells (Germinal center B-cell like-GCB). Skin defect cover was provided with scrotal skin remnants at the edge of the lesion 1 month later. The patient was discharged from the hospital 35 days later. Afterwards, he was treated with chemotherapeutic agents for malignant lymphoma at the oncological department.

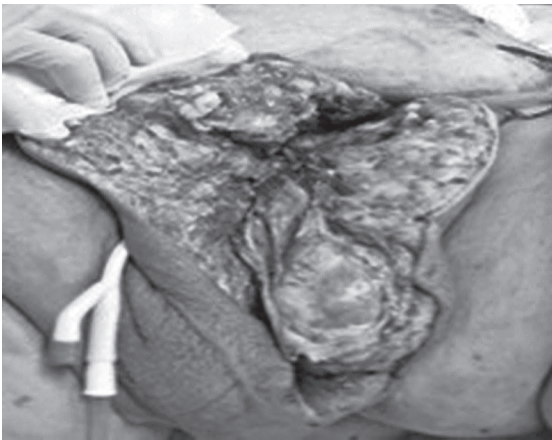


Figure 2 – The patient required urgent surgical debridement of the affected area, excision of necrotic tissue and pus drainage.

## Discussion

Fournier's gangrene is a polymicrobial necrotic infection of the scrotum and perineum which can be expanded to the Scarpa's fascia with a high mortality rate. The disease afflicts male more often than female (male/female: 10/1) (Eke, 2000). The source of microbes seems to be in rectum at 13–50% of the

cases, in urogenital system at 17–87% and in the skin at 21–24% (Smith et al., 1998; Vick and Carson, 1999; Dahm et al., 2000; Eke, 2000). Microbes which are usually isolated from pus and blood cultures are *Escherichia coli*, *Proteus*, *Klebsiella*, *Bacteroides fragilis*, *Streptococci* and *Staphylococci* (Smith et al., 1998; Eke, 2000; Yaghan et al., 2000). In some cases *Candida* can be also been responsible.

Predisposing factors for a person to develop the disease are diabetes mellitus (21–79% of cases), alcoholism (25–66% of cases), burns, local injuries (perineum trauma or after endoscopic or iatrogenic handlings), paraphimosis, perianal abscesses, genitalia infections, immunosuppression (HIV, chemotherapy drugs, lymphomas), filariasis, Richter's hernia, malnutrition, poor hygiene, and usage of injections (Eke, 2000; Yaghan et al., 2000). An obvious cause may not be found in 5% of cases (idiopathic). It remains controversial if obesity constitutes a predisposing factor for an individual to develop necrotizing fasciitis (Sorensen et al., 2009). On the other hand, only few cases of patients with coexistence of B-lymphoma and Fournier's gangrene disease have been reported (Yumura et al., 2000).

It seems reasonable that individuals with obesity can develop Fournier's gangrene since most of them often have diabetes mellitus, also. In our case, we had a young obese patient without a history of diabetes mellitus, which was also proven with laboratory exams. Pathological examination of the mass distinguished B-lymphoma, which seems to be related with Fournier's disease (Yumura et al., 2000).

Fournier's gangrene clinical appearance is almost similar with cellulitis. The difference is that cellulitis is a surface infection without necrotic tissue, while microbes in Fournier's disease cause infection of the small subdermal artery vessels which causes their thrombosis (Eke, 2000; Yaghan et al., 2000). Arterial thrombosis causes ischemic necrotic fasciitis, however muscle necrosis is rare. Local tissue hypoxia assists the anaerobic microbes' development. Furthermore, necrotic fasciitis can develop from toxic microbes' products such as collagenases and hyaluronidases of *Streptococci* and *Staphylococci*, coagulases of beta-hemolytic *Streptococci*, heparinases of some anaerobic bacteria and lipopolysaccharidases of gram(–) bacteria (Smith et al., 1998; Vick and Carson, 1999).

Treatment must start immediately including vital support, intravenous antibiotics, urgent surgical debridement of the affected area and excision of necrotic tissue. Intravenous antibiotic treatment should be prescribed immediately, as soon as blood cultures are received. Triple antibiotic schema containing Penicillin G or Ampicillin (for G+ microbes), Aminoglycoside or Cephalosporin 3<sup>rd</sup> generation (for G–) and Metronidazole or Clindamycine (for the anaerobic microbes) is recommended (Vick and Carson, 1999).

Treatment with hyperbaric oxygen has been proposed, due to the contamination with anaerobic microbes, such as *Clostridium*. The benefit of this therapeutic approach has not documented yet (Eke, 2000; Yaghan et al., 2000). Honey spreading in the surgical area has also been proposed as a complementary therapy because of its antimicrobial and faster healing potential (Tahmaz et al., 2006).

## Conclusion

Young obese patients with Fournier's gangrene disease should be particularly investigated due to the possible occurrence of another not obvious predisposing factor, such as a B-lymphoma disease.

## References

- Dahm, P., Roland, F. H., Vaslef, S. N., Moon, R. E., Price, D. T., Georgiade, G. S., Vieweg, J. (2000) Outcome analysis in patients with primary necrotising fasciitis of the male genitalia. *Urology* **56(1)**, 31–36.
- Eke, N. (2000) Fournier's gangrene: a review of 1726 cases. *Br. J. Surg.* **87(6)**, 718–728.
- Fournier, J. A. (1883) Gangrene foudroyante de la verge. *Med. Pract. Paris* **4**, 589–597.
- Smith, G. L., Bunker, C. B., Dinneen, M. D. (1998) Fournier's gangrene. *Br. J. Urol.* **81(3)**, 347–355.
- Sorensen, M. D., Kriequer, J. N., Rivara, F. P., Broghammer, J. A., Klein, M. B., Mack, C. D., Wessels, H. (2009) Fournier's gangrene: population based epidemiology and outcomes. *J. Urol.* **181(5)**, 2120–2126.
- Tahmaz, L., Erdemir, F., Kibar, Y., Cosar, A., Yalcyn, O. (2006) Fournier's gangrene: report of thirty-three cases and a review of the literature. *Int. J. Urol.* **13(7)**, 960–967.
- Vick, R., Carson, C. C. 3<sup>rd</sup> (1999) Fournier's disease. *Urol. Clin. North Am.* **26(4)**, 841–849.
- Wilson, B. (1952) Necrotising fasciitis. *Am. J. Surg.* **18(4)**, 416–431.
- Yaghan, R. J., Al-Jaberi, T. M., Bani-Hani, I. (2000) Fournier's gangrene: changing face of the disease. *Dis. Colon Rectum* **43(9)**, 1300–1308.
- Yumura, Y., Chiba, K., Saito, K., Hirokawa, M. (2000) Fournier's gangrene in a patient with malignant lymphoma: a case report. *Hinyokika Kyo* **46(10)**, 735–737. (in Japanese)