

Serious Complication of Percutaneous Angioplasty with Stent Implantation in so Called “Chronic Cerebrospinal Venous Insufficiency” in Multiple Sclerosis Patient

Doležal O.¹, Horáková D.¹, Gdovinová Z.², Szilasiová J.²

¹Department of Neurology and Center of Clinical Neuroscience, First Faculty of Medicine, Charles University in Prague and General University Hospital in Prague, Prague, Czech Republic;

²Department of Neurology, Faculty of Medicine, Pavol Jozef Šafárik University, Košice, Slovak Republic

Received October 24, 2011; Accepted October 10, 2012.

Key words: Multiple sclerosis – Chronic cerebrospinal venous insufficiency – Percutaneous angioplasty – Stent – Thrombosis

Abstract: We report female patient, age 51, with clinically definitive multiple sclerosis (CDMS) since 1998, who underwent two PTA procedures with stent implantation for CCSVI in 2010. Expanded disability status scale (EDSS) worsened since the procedure from 4.5 to 6. Total number of three stents was implanted (two of them in the right internal jugular vein). In six month time, in 2011, patient was referred for independent examination by computer tomography (CT) phlebography for right-sided neck pain. Dislocation of stents on the right side and thrombosis of left sided stent was found. Conservative approach was used so far. Our short report is showing possible complications of PTA and stenting in jugular veins in so called CCSVI and bringing information about neurological state (EDSS) worsening in a subject. Continuation of stent migration in the future is probable, possibly resulting in pulmonary embolism with fatal risk for the patient. We strongly ask for restriction of PTA procedure in so called CCSVI, which concept was not proven to be relevant to MS.

Mailing Address: Ondřej Doležal, MD., PhD., Department of Neurology and Center of Clinical Neuroscience, First Faculty of Medicine, Charles University in Prague and General University Hospital in Prague, Kateřinská 30, 120 00 Prague 2, Czech Republic; Mobile Phone: +420 603 239 509; e-mail: odol.cuni.cz@gmail.com

© Charles University in Prague – Karolinum Press, Prague 2012

Introduction

Chronic cerebrospinal venous insufficiency (CCSVI) is recently widely discussed new factor in multiple sclerosis (MS) pathogenesis (Zamboni et al., 2008, 2009a, b). Etiological link between disease itself and probable venous insufficiency was not proven (Doepp et al., 2010; Khan et al., 2010; Centonze et al., 2011; Ghezzi et al., 2011; Mayer et al., 2011; Tanaka et al., 2011; Wattjes et al., 2011; Zivadinov et al., 2011). Many theories appeared in connection with this concept and possible mechanism of action. The two most popular theories included “pressure based theory”, suggesting disruption of brain-blood barrier connected with white blood cells invasion and immunological theory suggesting cumulation of non specified “toxins” such as viruses, cytokines etc. (Doležal, 2011).

Percutaneous transluminal angioplasty (PTA), sometimes with stent implantation, was offered as a solution by some physicians around the world, however this approach brought a lot of controversy. Reports about severe complications emerged (Ludyga et al., 2010; Reekers et al., 2011; Simka, 2011; Thapar et al., 2011). Our report describes a female patient with secondary progressive multiple sclerosis (SPMS), who underwent bilateral internal jugular vein PTA and stent implantation.

Case presentation

We report female patient, Caucasian, age 51, with clinically definitive MS (CDMS) since 1998. Expanded disability status scale (EDSS) was 4.5 at the time of procedure. Patient was treated with interferon Beta 1b. This patient decided to be tested for presence of CCSVI; she underwent first ultrasound examination focusing on presence of CCSVI in Poland in March 2010. According to treating physician she fulfilled criteria for CCSVI, namely bilateral “jugular stenosis” and PTA was indicated. PTA was performed on both sides and stent was applied on the right side. Patient was released to homecare after one day of hospitalization. She was treated with antiplatelet drugs (clopidogrel 75 mg/day, acetylsalicylic acid 100 mg/day) and temporarily with low molecular weight heparin (LMWH). Patient was checked up regularly by physician who performed first diagnostics and procedure. In July 2010 bilateral “restenosis” of internal jugular vein was diagnosed. Another PTA was performed. Second stent was inserted on the right side and new stent was applied to left internal jugular vein as well. Antiplatelet drugs and LMWH therapy was continued. In September 2010 patient was examined at home (Slovakia) for right sided neck pain. CT phlebography showed on the right side dislocation of proximal stent from jugular vein to brachiocephalic vein and partially to superior vena cava and dislocation of distal stent downwards as well, without signs of thrombosis. Thrombosis of stent was found on the left side (Figure 1). Patient was not suffering from known procoagulation state. Conservative approach including anticoagulation therapy (LMWH 10,000 unit/day) and antiplatelet

Doležal O.; Horáková D.; Gdovinová Z.; Szilasiová J.

treatment (clopidogrel 75 mg/day) was indicated. In December 2010 re-canalization of left sided stent was found. In June 2011 patient was examined by neurologist, EDSS was 6, especially worsening of spastic paraparesis and sphincter dysfunction was found.

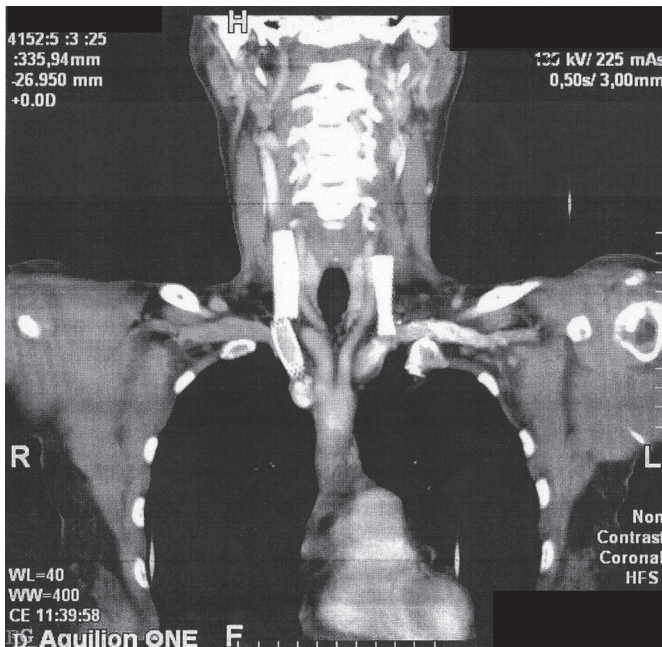


Figure 1 – CT phlebography showed on the right side dislocation of proximal stent from jugular vein to brachiocephalic vein and partially to superior vena cava and dislocation of distal stent downwards as well, without signs of thrombosis. Thrombosis of stent was found on the left side.

Discussion

Our short report is showing possible and expected complication of PTA and stenting in jugular and potentially any other vein in so called “CCSVI”. We would like to emphasize the fact that even existence of CCSVI is a subject to controversy (Zamboni et al., 2009a, b; Doepp et al., 2010; Khan et al., 2010; Ghezzi et al., 2011; Mayer et al., 2011; Zivadinov et al., 2011). Other independent and unbiased studies are conducted in the presence and results are expected. Term of venous stenosis is inaccurate. Thinner calibre of vein does not automatically mean venous insufficiency and vice versa, large dilated veins do not mean adequate venous function. Whole concept of endovascular treatment of venous insufficiency is incorrect and does not respect basic physiological and physical principles. Procedure itself can damage valve structures and alter their function. Our report is also one of the first bringing an information about neurological state

Complications of CCSVI Therapy

worsening in a subject. EDSS in our patient worsened from 4.5 to 6 within one year. Another question we can address but cannot answer is a future development of the case. Continuation of stent migration in the future is probable, possibly resulting in pulmonary embolism with fatal risk for the patient. According to our opinion, conservative approach, including regular ultrasound and CT angiography examinations, should be used, because dislocated stents are extremely difficult to remove, especially from superior vena cava, with relatively high risk for subject.

References

- Centonze, D., Floris, R., Stefanini, M., Rossi, S., Fabiano, S., Castelli, M., Marziali, S., Spinelli, A., Motta, C., Garaci, F. G., Bernardi, G., Simonetti, G. (2011) Proposed chronic cerebrospinal venous insufficiency criteria do not predict multiple sclerosis risk or severity. *Ann. Neurol.* **70**, 52–59.
- Doepf, F., Paul, F., Valdueza, J. M., Schmierer, K., Schreiber, S. J. (2010) No cerebrocervical venous congestion in patients with multiple sclerosis. *Ann. Neurol.* **68**, 173–183.
- Doležal, O. (2011) Chronic cerebrospinal venous insufficiency in multiple sclerosis – Old-new concept, new questions? *Cesk. Slov. Neurol. N.* **74/107**, 357–360.
- Ghezzi, A., Comi, G., Federico, A. (2011) Chronic cerebro-spinal venous insufficiency (CCSVI) and multiple sclerosis. *Neurol. Sci.* **32**, 17–21.
- Khan, O., Filippi, M., Freedman, M. S., Barkhof, F., Dore-Duffy, P., Lassmann, H., Trapp, B., Bar-Or, A., Zak, I., Siegel, M. J., Lisak, R. (2010) Chronic cerebrospinal venous insufficiency and multiple sclerosis. *Ann. Neurol.* **67**, 286–290.
- Ludyga, T., Kazibudzi, M., Simka, M., Hartel, M., Swierad, M., Piegza, J., Latacz, P., Sedlak, L., Tochowicz, M. (2010) Endovascular treatment for chronic cerebrospinal venous insufficiency: is the procedure safe? *Phlebology* **25**, 286–295.
- Mayer, C. A., Pfeilschifter, W., Lorenz, M. W., Nedelmann, M., Bechmann, I., Steinmetz, H., Ziemann, U. (2011) The perfect crime? CCSVI not leaving a trace in MS. *J. Neurol. Neurosurg. Psychiatry* **82**, 436–444.
- Reekers, J. A., Lee, M. J., Belli, A. M., Barkhof, F. (2011) Cardiovascular and Interventional Radiological Society of Europe commentary on the treatment of chronic cerebrospinal venous insufficiency. *Cardiovasc. Intervent. Radiol.* **34**, 1–2.
- Simka, M. (2011) Commentary: Safety of endovascular treatment for CCSVI and future perspectives. *J. Endovasc. Ther.* **18**, 326–327.
- Tanaka, M., Uchizumi, H., Tanaka, K. (2011) Evaluation of blood flow and the cross-sectional area of internal jugular vein in Japanese multiple sclerosis and neuromyelitis optica patients. *Rinsho Shinkeigaku* **51**, 430–432. (in Japanese)
- Thapar, A., Lane, T. R., Pandey, V., Shalhoub, J., Malik, O., Ellis, M., Franklin, I. J., Nicholas, R., Davies, A. H. (2011) Internal jugular thrombosis post venoplasty for chronic cerebrospinal venous insufficiency. *Phlebology* **26**, 254–256.
- Wattjes, M. P., Doepf, F., Bendszus, M., Fiehler, J. (2011) “Chronic cerebrospinal venous insufficiency” in multiple sclerosis – is multiple sclerosis a disease of the cerebrospinal venous outflow system? *Rofo* **183**, 523–530. (in German)
- Zamboni, P., Lanzara, S., Mascoli, F., Caggiati, A., Liboni, A. (2008) Inflammation in venous disease. *Int. Angiol.* **27**, 361–369.
- Zamboni, P., Galeotti, R., Menegatti, E., Malagoni, A. M., Giancesini, S., Bartolomei, I., Mascoli, F., Salvi, F. (2009a) A prospective open-label study of endovascular treatment of chronic cerebrospinal venous insufficiency. *J. Vasc. Surg.* **50**, 1348–1358.

Doležal O.; Horáková D.; Gdovinová Z.; Szilasióvá J.

- Zamboni, P., Galeotti, R., Menegatti, E., Malagoni, A. M., Tacconi, G., Dall'Ara, S., Bartolomei, I., Salvi, F. (2009b) Chronic cerebrospinal venous insufficiency in patients with multiple sclerosis. *J. Neurol. Neurosurg. Psychiatry* **80**, 392–399.
- Zivadinov, R., Marr, K., Cutter, G., Ramanathan, M., Benedict, R. H., Kennedy, C., Elfadil, M., Yeh, A. E., Reuther, J., Brooks, C., Hunt, K., Andrews, M., Carl, E., Dwyer, M. G., Hojnacki, D., Weinstock-Guttman, B. (2011) Prevalence, sensitivity, and specificity of chronic cerebrospinal venous insufficiency in MS. *Neurology* **77**, 138–144.