

Serum Levels of Antibodies to Thyroid Peroxidase Correlate with Quantitative Descriptors of Thyroid Ultrasound Images in Patients with Breast Cancer

**Jiskra J.¹, Smutek D.¹, Barkmanová J.², Antošová M.¹,
Límanová Z.¹, Potluková E.¹, Sucharda P.¹**

¹Third Medical Department of the First Faculty of Medicine, Charles University in Prague, Czech Republic;

²Oncological Department of the First Faculty of Medicine, Charles University in Prague, Czech Republic²

Received September 29, 2005, Accepted November 16, 2005

Key words: Breast cancer – Echogenity – Raw grey scale – Texture – Antibodies to thyroid peroxidase – Free thyroxin

This work was supported by the grant IGA MZ ČR NR8130-3.

Mailing Address: Jan Jiskra MD., PhD., Third Medical Department of the First Faculty of Medicine and General Teaching Hospital, U Nemocnice 1, 128 08 Prague 2, Czech Republic, Phone: +420 608 906 900, Fax: +420 224 919 780, e-mail: jan.jiskra@seznam.cz

Abstract: The aim of the study was to compare the structural changes in ultrasound image of the thyroid tissue in 12 women with breast cancer (BC) and 8 women with colorectal cancer (CC). MATLAB software was used to analyse the digitised images. As quantitative descriptors of thyroid ultrasound images (QDTI) were used raw grey scale values of individual image pixels (RAW) and the optimal one-dimensional discriminative texture features (F2, F6, F7). The possible relations between QDTI and thyroid laboratory parameters were tested. In the BC group serum levels of antibodies to thyroid peroxidase negatively correlated with feature RAW (multiple regression, beta coefficient -0.75 , $p=0.004$) and positively with feature F2 (multiple regression, beta coefficient 1.44 , $p=0.04$). In the BC group RAW negatively correlated with serum levels of tumour marker CA 15-3 (Pearson's correlation coefficient, $r=-0.714$, $p=0.00917$). No such correlations were found in CC group. The correlations between QDTI and serum levels of antibodies to thyroid peroxidase in patients with BC show that the positivity of antibodies to thyroid peroxidase is probably accompanied with structural changes in the thyroid tissue.

Introduction

The association of autoimmune thyroiditis (AIT) with several autoimmune diseases such as diabetes mellitus type I or celiac disease is generally known [1]. In contrast, although it has been the subject of study for a long time, the relationship between AIT and some non-autoimmune diseases, e.g. breast cancer is not fully understood. A sonographic enlargement of the thyroid gland [2, 3], a higher percentage of positivity of antibodies to thyroid peroxidase (TPO-ab) (15.2–37.7 percent according to several studies [3, 4, 5, 6]), a higher percentage of positivity of antibodies to thyroglobulin (TGB-ab) (15.2 percent [7]) and increased serum levels of thyroid-stimulating hormone (TSH) (10.3–19.7 percent [7, 8]) have been found in women with breast cancer in comparison with healthy women.

Autoimmune thyroiditis (AIT) is a chronic inflammation of the thyroid gland [9]. AIT can be diagnosed from clinical examination, analysis of hormones and thyroid autoantibodies in blood, and from cytological examination using fine needle aspiration biopsy. However, because the autoimmune inflammation leads to the focal or diffuse structural changes of the thyroid tissue, it can be also detected by ultrasonography [10, 11, 12]. Typical ultrasound features of AIT are the focal or diffuse hypoechogenities and non-homogenous structure. Unfortunately, the evaluation of the thyroid echogenity and homogeneity is to a great extent subjective, and can be often different in relation to several examiners. Therefore, the aim of the study was to compare the focal or diffuse structural changes of the thyroid tissue in patients with breast cancer (BC) and colorectal cancer (CC) with use of quantitative descriptors of thyroid ultrasound image. Furthermore, a possible relationship between quantitative descriptors and serum levels of thyroid laboratory parameters (TSH, free thyroxin – FT4, TPO-ab and TGB-ab) and serum

levels of tumour markers CEA (carcinoembryonal antigen), CA 15-3 and CA 19-9 was evaluated.

Patients and methods

Patients

We investigated 20 randomly chosen women with oncological diseases, 12 with breast cancer (BC) and 8 with colorectal cancer (CC). Both groups were age-comparable (Table 1). All of these patients had undergone a breast or colorectal surgical intervention and all were from the same geographic area (Prague, Czech Republic). Family and personal history with respect to autoimmune, endocrine and oncological diseases were obtained from the subjects, and they all underwent clinical examination and thyroid ultrasonography. An informed verbal consent was obtained from all participants and the procedures followed were in accordance with the ethical standards of our institution's committee on human experimentation.

Laboratory analysis

In all subjects the chemiluminescence method was used to investigate the serum levels of thyroid-stimulating hormone (TSH), free thyroxin (FT4), antibodies to thyroid peroxidase (TPO-ab), antibodies to thyroglobulin (TGB-ab) and the serum levels of tumour markers CEA (carcinoembryonal antigen), CA 15-3 and CA 19-9. According to what is presently known about subclinical hypothyroidism the following were taken to be normal values: TSH 0.5–3.5 mIU.l⁻¹ [13, 14], FT4

Table 1 – Thyroid laboratory parameters and quantitative descriptors of thyroid ultrasound images in women with breast cancer and colorectal cancer

	breast cancer	colorectal cancer	p
n	12	8	
age*	67 ± 8.37	64 ± 14.64	0.701 ²
FT4*	14.5 ± 2.01	12.95 ± 2.53	0.144 ²
TSH**	1.56 (1.26...3.53)	3.12 (1.07...6.49)	0.787 ¹
TPO-ab**	31.15 (32.60...62.40)	26.2 (20.25...85.25)	0.464 ¹
TGB-ab**	54.40 (43.35...88.50)	54.40 (45.8...58.80)	0.908 ¹
RAW*	10.63 ± 2.48	12.17 ± 3.38	0.253 ²
F2*	261.61 ± 42.90	248.14 ± 20.64	0.425 ²
F6*	422.51 ± 14.25	422.03 ± 16.70	0.947 ²
F7*	442.79 ± 78.04	425.40 ± 55.11	0.597 ²

TSH: serum levels of thyroid-stimulating hormone (mIU.l⁻¹), FT4: serum levels of free thyroxin (pmol.l⁻¹), TGB-ab: serum levels of antibodies to thyroglobulin (kIU.l⁻¹), TPO-ab: serum levels of antibodies to thyroid peroxidase (kIU.l⁻¹), n: number of patients, RAW: raw grey scale values of individual image pixels, F2, F6, F7: the optimal one-dimensional discriminative texture features, * normality test passed, ** normality test failed, ¹Mann-Whitney test: expressed as median, lower quartile (25 %), upper quartile (75 %), ²t-test: expressed as mean value ± standard deviation, p: level of significance

9.8–23.1 pmol.l⁻¹, TGB-ab <60 kIU.l⁻¹, TPO-ab <60 kIU.l⁻¹, CEA 0–5.0 ug.l⁻¹, CA 15-3 0–31.0 kIU.l⁻¹ and CA 19-9 0–37.0 kIU.l⁻¹.

Sonographic examination and computerised analysis of ultrasound images

A sonographic examination of the thyroid gland was performed in all subjects at the sonographic department of the 3rd Medical Department of the 1st Medical Faculty of the Charles University in Prague. Volume (ml), echogenity (low, normal, and high), structure (homogenous, non-homogenous), perfusion (low, normal, and high) and a possible nodulisation were evaluated. A sonographic imaging system Toshiba ECCO-CEE (console model SSA-340A, Otawara, Tochigi 324, Japan) equipped with an 8-MHz linear probe (model PLF-805ST), allowing a maximum depth of examination 40 mm, frame rate 19 Hz, was used. The RS170 output from the sonograph was digitised using Data Translation DT3155 frame-grabber. B-mode images with grey scale with 256 levels and 415x381 pixels were recorded. In order to determine reproducible echo levels, constant sonographic operating conditions were defined. The following parameters (adjustable functions of the console, using manufacturer's terms for the functions) on the sonograph were fixed to the same values as when used for routine examination, i.e., a gain of 92, medium sensitivity by depth, maximal acoustic power, and maximum spatial resolution. In order to include the sufficient amount of diagnostically relevant information the scans were taken for several (10 for each lobe) probe positions placed in parallel with each other and separated by arbitrary separations, within the range of 10 mm, according to the physician's decision. Only longitudinal cross-sections were used in our study, because they provide greater amount of image data from a larger contiguous area of the gland tissue [15]. MATLAB software (The MathWorks, Inc., Nattick, MA, USA) was used to analyse the digitised images. The boundary of the gland was roughly delineated and the region for analysis was selected manually by a physician, as illustrated by the outline in Figure 1. As

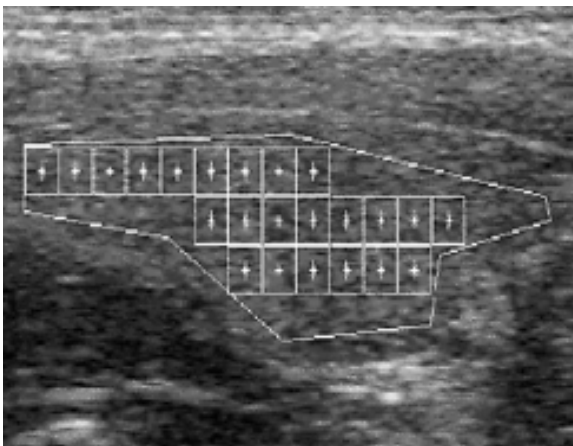


Figure 1 – Sonographic image (longitudinal scan of right lobe) with drawn boundary of thyroid gland and texture samples (rectangular windows of 41x41 pixels).

quantitative indicators of image (texture description), raw grey scale values of individual image pixels (RAW) and the optimal one-dimensional discriminative texture features were used (F2 F6, F7) [16]. F2 is derived using the Kolmogorov-Smirnov distance between an estimate of the cumulative distribution function and the robust estimate of the cumulative distribution function mean, both computed for difference from sample mean. F6 and F7 represent the Euclidean distance from original pixel grey levels and their four grey-level transformations to their mean and median, respectively. As the next step the mean values of RAW, F2, F6 and F7 were calculated and assigned to each subject.

Statistical analysis

The results were statistically analysed by multiple regression, t-test, Mann-Whitney test, Pearson's correlation coefficient and Spearman rank order correlation coefficient employing the Sigmatat program (Jandel Scientific, USA).

Results

No significant differences (t-test, Mann-Whitney test) of mean values of grey scale value-RAW and more complex texture image features (F2, F6 and F7) and medians of serum levels of TSH, FT4 (markers of thyroid function), TPO-ab and TGB-ab (markers of thyroid autoimmunity) were observed between BC and CC groups of patients (Table 1).

Significant positive correlations (Spearman rank order correlation coefficient) between TSH and TPO-ab ($r=0.652$, $p<0.05$, $n=12$) and TPO-ab and TGB-ab ($r=0.645$, $p<0.05$, $n=12$) were found in the BC group.

Multiple regressions was performed for TPO-ab (dependent variable) and grey scale value-RAW (independent variable) in BC and CC groups. In women with BC the correlation with multiple R-Square (coefficient of determination) 0.57 (F-test 13.11, $p=0.004$) was detected. The TPO-ab serum levels negatively correlated with RAW with beta coefficient -0.75 and $p=0.004$ (Figure 2).

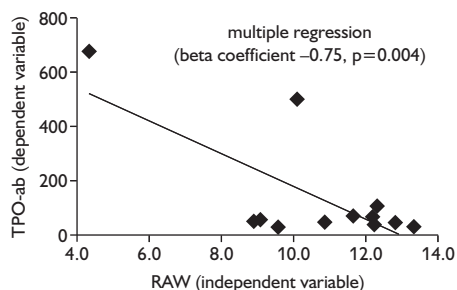


Figure 2 – Negative correlation between TPO-ab and RAW in subjects with breast cancer.

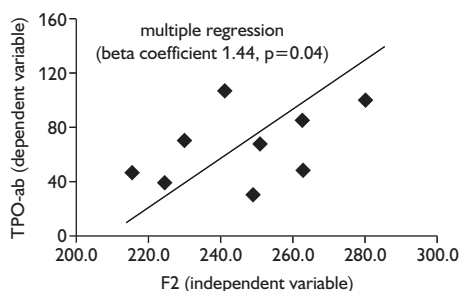


Figure 3 – Positive correlation between F2 and TPO-ab in subjects with breast cancer.

Furthermore, multiple regression was performed for TPO-ab (dependent variable) and more complex texture image features (F2, F6 and F7). In subjects with BC the correlation with multiple R-Square (coefficient of determination) 0.77 (F-test 6.0, $p=0.02$) was detected: the TPO-ab positively correlated with feature F2 with beta coefficient 1.44 and $p=0.04$ (Figure 3).

Moreover, in the BC group the significant negative correlation (Pearson's correlation coefficient) between FT4 and F7 ($r=-0.650$, $p=0.0303$, $n=12$) was observed (Table 2).

In contrast, in the subjects with CC, except of the significant negative correlation (Pearson's correlation coefficient) between FT4 and F2 ($r=-0.805$, $p=0.0159$, $n=8$), no similar correlations were found (Table 3).

Finally, Pearson's correlation coefficient and Spearman rank order correlation coefficient were carried out for evaluating of possible relations between thyroid laboratory parameters and ultrasound texture image features and serum levels of tumour markers. In the BC group a significant negative correlation between FT4

Table 2 – Pearson's correlation coefficient in breast cancer group

	FT4	CEA	CA 15-3
RAW	$r= 0.510$ $p= 0.09$	$r= - 0.332$ $p= - 0.291$	$r= - 0.714$ $p= 0.00917$
F2	$r= - 0.544$ $p= 0.0835$	$r= 0.0969$ $p= 0.777$	$r= 0.483$ $p= 0.132$
F6	$r= - 0.433$ $p= 0.183$	$r= - 0.197$ $p= 0.561$	$r= 0.0659$ $p= 0.847$
F7	$r= - 0.650$ $p= 0.0303$	$r= 0.307$ $p= 0.395$	$r= 0.762$ $p= 0.00642$

FT4: serum levels of free thyroxin (pmol.l^{-1}), CEA: serum levels of cacrinoembryonal antigen (ug.l^{-1}), CA 15-3: serum levels of tumour marker CA 15-3 (klU.l^{-1}), RAW: raw grey scale values of individual image pixels, F2, F6, F7: the optimal one-dimensional discriminative texture features, r: Pearson's correlation coefficient, p: level of significance, bold: significant correlations ($p<0.05$)

Table 3 – Pearson's correlation coefficient in colorectal cancer group

	FT4	CEA	CA 19-9
RAW	$r= - 0.244$ $p= 0.560$	$r= 0.0820$ $p= 0.874$	$r= - 0.410$ $p= 0.313$
F2	$r= - 0.805$ $p= 0.0159$	$r= - 0.517$ $p= 0.190$	$r= - 0.283$ $p= 0.497$
F6	$r= - 0.090$ $p= 0.832$	$r= - 0.474$ $p= 0.236$	$r= - 0.130$ $p= 0.759$
F7	$r= 0.050$ $p= 0.768$	$r= - 0.212$ $p= 0.614$	$r= 0.0565$ $p= 0.894$

FT4: serum levels of free thyroxin (pmol.l^{-1}), CEA: serum levels of cacrinoembryonal antigen (ug.l^{-1}), CA 19-9: serum levels of tumour marker CA 19-9 (klU.l^{-1}), RAW: raw grey scale values of individual image pixels, F2, F6, F7: the optimal one-dimensional discriminative texture features, r: Pearson's correlation coefficient, p: level of significance, bold: significant correlations ($p<0.05$)

and CA 15-3 serum levels was observed (Pearson's correlation coefficient, $r=-0.685$, $p=0.0140$, $n=12$). Moreover, in the BC group the serum levels of CA 15-3 negatively correlated with RAW (Pearson's correlation coefficient, $r=-0.714$, $p=0.00917$, $n=12$) (Table 2, Figure 4) and positively with feature F7 (Pearson's correlation coefficient, $r=0.762$, $p=0.00642$, $n=12$) (Table 2, Figure 5). In contrast, no such correlations were found in the CC group (Table 3).

In both groups, no significant correlations between thyroid laboratory parameters (FT4, TSH, TGB-ab and TPO-ab) and ultrasound texture image features (RAW, F2, F6 and F7) and serum levels of CEA and CA 19-9 were observed.

Discussion

Although it has been the subject of study for a long time, the relationship between AIT and breast cancer is not fully understood. A sonographic enlargement of the thyroid gland [2, 3] and a high percentage of positivity of antibodies to thyroid peroxidase (TPO-ab) (nearly 37.7% according to several studies [3, 4, 5, 6] have been documented in women with breast cancer in comparison with healthy women. Moreover, in our previous study we found increased serum levels of thyroid-stimulating hormone (TSH) in 19.7%, positivity of antibodies to thyroglobulin (TGB-ab) and TPO-ab in 15.2% of women with breast cancer in comparison with 14.7, resp. 10.3, resp. 11.8 percent in women with colorectal cancer and 12.3, resp. 10.2, resp. 12.3 percent in women with healthy thyroid glands [7]. Similarly, a sonographic enlargement of the thyroid gland has been described in 80 % and TPO-ab positivity in 28% of women with benign fibrocystic mastopathies [4, 17]. Through the use of fine-needle-aspiration biopsy, AIT has been confirmed in 19 of 310 (13.23%) women with breast cancer [5].

Despite that a linkage between AITD and breast cancer was described in literature, to our knowledge there is not a study (excepting of the studies measured the thyroid volume) concerned with quantitative ultrasound image

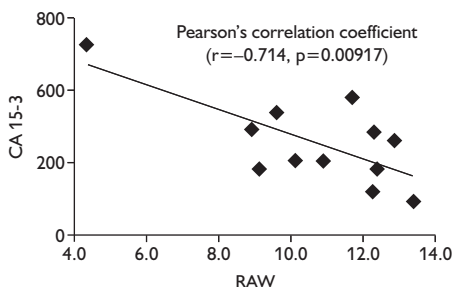


Figure 4 – Significant negative correlation between CA 15-3 and RAW in subjects with breast cancer.

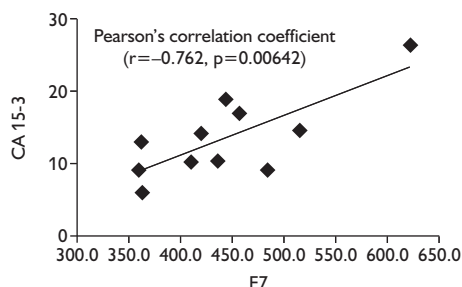


Figure 5 – Significant positive correlation between CA 15-3 and F7 in subjects with breast cancer.

texture features of the thyroid gland in patients with breast cancer. Similarly there is no a published work concerning a possible relationship between the thyroid laboratory parameters (TSH, FT4, TGB-ab and TPO-ab) and serum levels of tumour markers (CEA and CA 15-3).

In our previous work we have found out that there is a significant relation between laboratory parameters of thyroid autoimmunity (TPO-ab and TGB-ab) and quantitative descriptors of ultrasound image [16]. Another our study has confirmed that the quantitative descriptors of ultrasound image significantly differ between patients with AIT and healthy controls, but moreover, it has shown that there are a differences both between women with oncological diseases and healthy controls and between women with AIT and oncological diseases [18].

Therefore, the aim of the present study was to find out whether there is a relation between quantitative descriptors of thyroid ultrasound image and thyroid laboratory parameters (TSH, FT4, TPO-ab and TGB-ab) in women with breast cancer and whether this relation is expressed in patients with colorectal cancer too.

The presence of the negative correlations between RAW and TPO-ab and F7 and FT4 and positive correlation between F2 and TPO-ab supports the opinion that there is a relation between the autoimmune thyroid diseases and breast cancer. These results are in concordance with findings in literature [2, 3, 4] and show, that the high positivity of TPO-ab in patients with breast cancer is also accompanied with structural changes in thyroid gland, typically found in autoimmune thyroiditis. On the contrary, the fact that no similar relations between thyroid laboratory parameters (TSH, FT4, TPO-ab and TGB-ab) and ultrasound image texture features were found in subjects with colorectal cancer suggests, that the positivity of TPO-ab and TGB-ab described in patients with colorectal cancer could be only a result of an increased immune reactivity in blood goes with oncological disease, and is not a consequence of autoimmune thyroiditis.

An extensive retrospective study of 9520 women with breast cancer in Massachusetts General Hospital has suggested that the survival rate of patients with contemporary autoimmune thyroiditis is higher in comparison with women with healthy thyroid glands [19]. Similar results have been obtained in Smyth and Shering's studies [4, 20]. In a recent study, the presence of thyroid disease in Turkish women with breast cancer was associated with reduction of the number of metastatic lymph nodes, vascular invasion and tumour size [21]. However, there is not a sufficient prospective mortality study, and thus, the influence of the presence of autoimmune thyroiditis on the outcome of women with breast cancer is controversial. According to our opinion, the significant negative correlation between CA 15-3 and RAW and positive correlation between CA 15-3 and F7 found in our study suggest, that increased RAW and decreased F7 values (usually found in autoimmune thyroiditis) could be linked with the advanced stages of breast cancer.

Conclusion

This work is one of the first practical applications of computerized analysis of thyroid ultrasound image in clinical medicine and clinical research. The correlations between quantitative descriptors of ultrasound image (texture features) and antibodies to thyroid peroxidase in patients with breast cancer show that the positivity of antibodies to thyroid peroxidase is probably accompanied with structural changes in the thyroid tissue. Our results demonstrate that the application of thyroid ultrasound texture analysis in future projects would help to the resolution of the all the time controversial question: whether there is a real linkage between the breast cancer and autoimmune thyroiditis or the yet known data are only a fiction.

References

1. JISKRA J., LÍMANOVÁ Z., VANÍČKOVÁ Z., KOCNA P.: IgA and IgG antigliadin, IgA anti-tissue transglutaminase and antiendomysial antibodies in patients with autoimmune thyroid diseases and their relationship to thyroidal replacement therapy. *Physiol. Res.* 52: 79–88, 2003.
2. SMYTH P. P., SMITH D. F., MCDERMOTT E. W., MURRAY M. J., GERAGHTY J. G., O'HIGGINS N. J.: A direct relationship between thyroid enlargement and breast cancer. *J. Clin. Endocrinol. Metab.* 81: 937–941, 1996.
3. SHERING S. G., ZBAR A. P., MORIARTY M., MCDERMOTT E. W., O'HIGGINS N. J., SMYTH P. P.: Thyroid disorders and breast cancer. *Eur. J. Cancer. Prev.* 6: 504–506, 1996.
4. SMYTH P. P., SHERING S. G., KILBANE M. T., MURRAY M. J., MCDERMOTT E. W., SMITH D. F., O'HIGGINS N. J.: Serum thyroid peroxidase autoantibodies, thyroid volume, and outcome in breast cancer. *J. Clin. Endocrinol. Metab.* 83: 2711–2716, 1998.
5. GOGAS J., KOUSKOS E., TSELENI-BALAFOUTA S., MARKOPOULOS C., REVENAS K., GOGAS G., KOSTAKIS A.: Autoimmune thyroid disease in women with breast carcinoma. *Eur. J. Surg. Oncol.* 27: 626–630, 2001.
6. TURKEN O., NARIN Y., DEMIRBAS S., ONDE M. E., SAYAN O., KANDEMIR E. G., YAYLACI M., OZTURK A.: Breast cancer in association with thyroid disorders. *Breast. Cancer. Res.* 5: 110–113, 2003.
7. JISKRA J., LÍMANOVÁ Z., BARKMANOVÁ J., SMUTEK D., FRIEDMANNOVÁ Z.: Autoimmune thyroid diseases in women with breast cancer and colorectal cancer. *Physiol. Res.* 53: 693–702, 2004.
8. LÍMANOVÁ Z., BARKMANOVÁ J., FRIEDMANNOVÁ Z.: The frequent incidence of thyropathies in women with breast carcinoma. *Vnitř. Lek.* 44: 76–82, 1998.
9. WARTFSKY L., INGBAR S. H.: Disease of the Thyroid. In: Harrison's principles of internal medicine 12th ed. McGraw-Hill Inc., New York 1991, 1712.
10. BLUM M., GOLDMAN A. B., HERSKOVIC A., HERBERG J.: Clinical application of thyroid echography. *New Engl. J. Med.* 287: 1164–1169, 1972.
11. GOODING G. A.: Sonography of the thyroid and parathyroid. *Radiol. Clin. North. Am.* 31: 967–989, 1993.
12. LOEVNER L. A.: Imaging of the thyroid gland. *Semin. Ultrasound CT MRI* 17: 539–562, 1996.
13. BJORO T., HOLMEN J., KRUGER O., MIDTHJELL K., HUNSTAD K., SCHREINER T., SANDNES L., BROCHMANN H.: Prevalence of thyroid disease, thyroid dysfunction and thyroid peroxidase antibodies in a large unselected population. The Health Study of Nord-Trøndelag (HUNT). *Eur. J. Endocrinol.* 143: 639–737, 2000.

14. DAYAN C. M., SARAVAN P. AND BAYLY G.: Whose normal thyroid function is better – yours or mine? *The Lancet* 3: 353–354, 2002.
15. ŠÁRA R., SMUTEK D., SUCHARDA P., SVAČINA Š.: Systematic construction of texture features for Hashimoto's lymphocytic thyroiditis recognition from sonographic images. In: Quaglini S.: *Artificial Intelligence in Medicine, 8th Conference on Artificial Intelligence in Medicine in Europe*, Springer-Verlag, Berlin 2001, 339–348.
16. SMUTEK D., ŠÁRA R., SUCHARDA P., TJAHDADI T., ŠVEC M.: Image Texture Analysis of Sonograms in Chronic Inflammations of Thyroid Gland. *Ultrasound Med. Biol.* 29: 1531–1543, 2003.
17. MIZIA-STECH K., ZYCH F., WIDALA E.: Mastopathy and simple goiter–mutual relationship. *Przegl. Lek.* 55: 250–258, 1998.
18. SMUTEK D., JISKRA J., SUCHARDA P., TESAR L.: Possibilities of Thyroid Ultrasonography Comparison in Patients with Oncological and Autoimmune Thyroid Diseases. In: Alekxy M: *Proceedings of the Winter International Symposium on Information and Communication Technologies, WISICT 2004*, Cancun, Trinity College Dublin, Computer Science Press, 2004, 363–367.
19. GOLDMAN M. B., MONSON A. A., MALOOF F.: Benign thyroid disease and risk of death from breast cancer. *Oncology* 49: 461–466, 1992.
20. SHERING S. G., KILBANE M. T., SMITH D. F.: Thyroid autoimmunity – a positive prognostic factor in breast cancer. *J. Endocrinol.* 151: 106, 1997.
21. CENGİZ O., BOZKURT B., UNAL B., YILDIRIM O., KARABEYOĞLU M., EROĞLU A., KOCER B., ULAS M.: The relationship between prognostic factors of breast cancer and thyroid disorders in Turkish women. *J. Surg. Oncol.* 87: 19–25, 2004.