

# GIST of pancreas

**Krška Z.<sup>1</sup>, Pešková M.<sup>1</sup>, Povýšil C.<sup>2</sup>,  
Hořejš J.<sup>3</sup>, Sedláčková E.<sup>4</sup>, Kudrnová Z.<sup>5</sup>**

<sup>1</sup>First Surgical Department of the First Faculty of Medicine, Charles University in Prague, and General Teaching Hospital, Czech Republic;

<sup>2</sup>Institute of Pathology of the First Faculty of Medicine, Charles University in Prague, Czech Republic;

<sup>3</sup>Department of Radiodiagnosics of the First Faculty of Medicine, Charles University in Prague, Czech Republic;

<sup>4</sup>Department of Oncology of the First Faculty of Medicine, Charles University in Prague, Czech Republic;

<sup>5</sup>Central Hematology Laboratories of the First Faculty of Medicine, Charles University in Prague, and General Teaching Hospital, Czech Republic

Received February 23, 2005, Accepted May 3, 2005

**Abstract:** Authors present the case (from the year 2003) of a 38 years old patient, female with large tumor in the abdominal cavity. Preoperative differential diagnostic examination showed either tumor of pancreas or left liver lobe. The surgery confirmed large tumor body of the pancreas. Histological and immunohistochemical examination determined gastrointestinal stromal tumor (GIST) of the pancreas from autonomous nerves with malignant character. Tumor was radically removed. In the postoperative period regular follow up was done at the department of oncology, abdominal ultrasound every 3 months, CT scan every 6 month. 2.5 years after operation the patient has no problems, CT scan is without signs of recurrent diseases. The analysis of GIST was performed in agreement with contemporary knowledge. According to the references, our case report GIST of pancreas is the first of this kind (till 2003).

**Key words:** Stromal tumor – Pancreas – GIST

*This study supported by grant IGA MZ ČR NR8185-3.*

**Mailing Address:** Assoc. Prof. Zdeněk Krška, MD., PhD., First Surgical Department of the First Faculty of Medicine, Charles University, and General Teaching Hospital, U Nemocnice 2, 128 00 Prague 2, Phone: +420 224 962 215, e-mail: krskaz@vfn.cz

**Abbreviations:** GIST – gastrointestinal stromal tumor, GANT– gastrointestinal autonomic nerve tumor, GIT – gastrointestinal tract, CEA – carcinoembryonic antigen, CRP – C-reactive protein

### Case history

The patient was a 38 years old female, 164 cm, 94 kg. In August 2002, after a viral disease, she found a resistance in the left subcostal region, and at the same time she felt abdominal pain spreading to the back. She used Brufen (ibuprofen). She was subfebrile persistently and fatigued.

She underwent a comprehensive examination at the Department of Surgery, which revealed a mildly sensitive, palm-size resistance in the epigastrium. Also diabetes mellitus was diagnosed requiring a special diet, while the other laboratory tests were negative, including CEA and CA 19–9 markers. Only elevation of CRP was found with peak values of 24 mg/L, and a high sedimentation rate of 124/130.

Additional examinations were focused abdominal area with the results as follows:

*Sonography:* Large object spreading from the left lobe of the liver corresponding in its character to adenoma with regressive changes, most probably after bleeding.

*Gastroscopy:* The anterior wall of the fundus and antrum of the stomach seems to be edged out by extragastric pressure.

*CT:* Steatosis of the liver; the focus is located intraperitoneally on the left side in the epigastrium and mesogastrium with mildly heterogeneous fluid to semi-fluid content. A mild shading of the stomach contents after the application of the contrast agent and occasionally unclear wall suggests the absence of an abscess, although this should be considered at first. The focus is located as a continuation of the caudal edge of the left liver lobe, and attaches widely to the abdominal wall in the ventral direction, and to the stomach in the lateral and laterocranial direction, while it is closely related to the pancreas dorsally, and the body of the pancreas cannot be differentiated well against the mass, while the head and tail of the pancreas remains non-increased (Figure 1).

*Endosonography + transabdominal ultrasound:* A combined, strongly suspected tumor mass with a hemorrhage is seen in the area of the left epigastrium, with

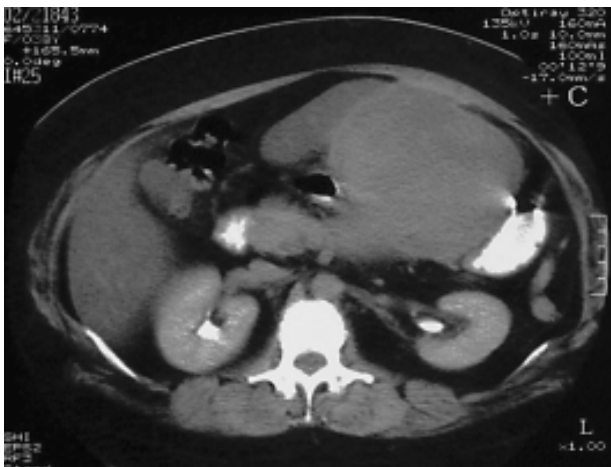

Figure 1 – CT of the abdomen and abdominal wall.

central vascularization well demonstrable by Doppler imaging and hematomas diffusely. Having the size of approx.  $17 \times 12 \times 10$  cm, the mass is encapsulated in the abdominal cavity, and cannot be separated in the ultrasound imaging from the lower part of the left liver lobe. No dilation of the bile ducts was found. A dilation of the pancreatic duct is visible up to 4 – 6 mm on the left side and in the tail of the pancreas, without any other clear pathologic findings in the sense of a focus or lesion in the parenchyma or chronic calcifying pancreatitis. The right part of the body and the transition area to the pancreas head cannot be examined completely due to the mass of tumor. An uneven, hypoechogenic lesion is seen in the cranial part of the medial half of the pancreas head affecting the parenchyma of the gland (2 cm wide), transforming into the picture with many foci, which extends ventrally away from the pancreas. The pancreatic duct in the head area is not dilated.

*Puncture under sonographic guidance:* The focus is soft, and hemorrhagic material is aspirated. This is clearly not an abscess.

*Preoperative cytology:* shows virtually only blood, with isolated stromal fragments, occasionally with signs of angiomatoid formations, not excluding the possibility of bleeding into the preformed hemangioma.

The set of preoperative examinations failed to provide a clear diagnosis. However, the examination clearly revealed a suspicion of a tumor in the abdominal cavity – a strongly suspected tumor of the left liver lobe or pancreas head. Therefore, a surgical revision was indicated and the patient was referred to the specialized inpatient facility.

Surgical revision of the abdominal cavity was carried out on 8 October 2002.

The findings from surgery confirmed a spherical tumor formation under the left liver lobe the size of an infant's head and attached to, but not originating from, the basal part of the left liver lobe (Figure 2). The mass was found to be

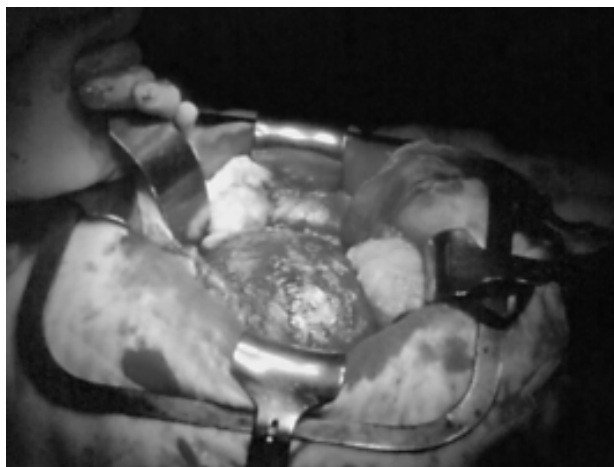

Figure 2 – Intraoperative view on the abdominal tumor.

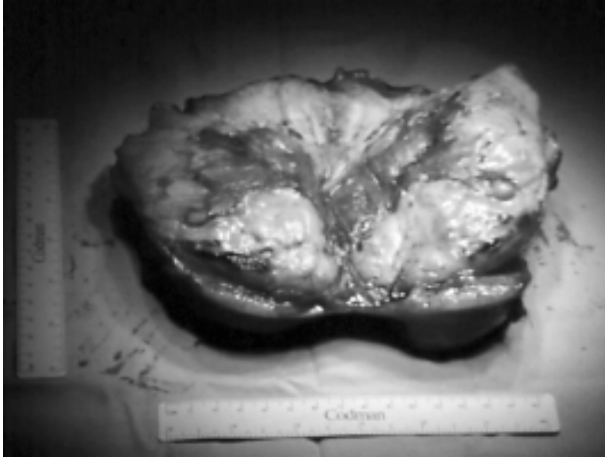


Figure 3 – Tumor cross-section.

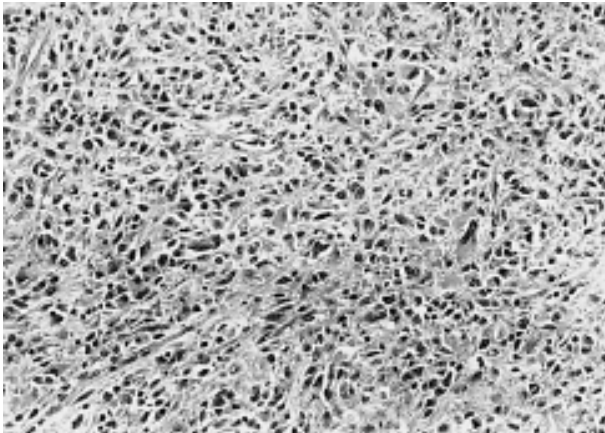


Figure 4 – Histology: the tumor was composed of a mixture of spindle and epithelioid cells with scattered atypical polymorphous elements. The tumor was strongly positive for CD 34 (HE stain,  $\times 80$ ).

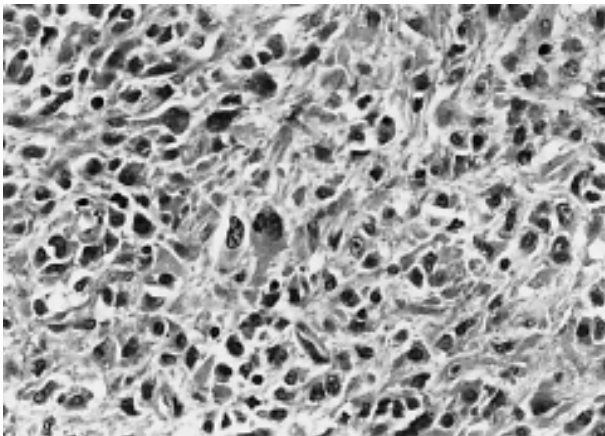


Figure 5 – Detail of the tumor cells of the pancreas. (HE stain,  $\times 250$ ).

attached to the body and partially to the head of the pancreas. The wall of the tumor was liberated and slid down from the hepatic artery and stomach wall. The capsule of the tumor lines the upper mesenteric vein and the confluence of the splenic vein and the porta; part of the capsule was left due to a high risk of damage to these structures. After removing the tumor, which had the weight of 1025 grams, the resection of the residues of the tumor of the head and body was completed in the sound tissue of the pancreas, and in the area of entrance of the splenic artery into the gland (Figure 3). The splenic vein was removed along with the destroyed body of the pancreas; the right side of the pancreas was closed blindly, while the excluded loop according to Roux was connected to the left part. When completing the revision of the preparation, we could clearly confirm that the tumor did not originate in the duodenum, as the mucosa and the wall of the duodenum could be examined and recognised throughout the entire length, and it did not originate in the Vater Papilla. The tumor didn't originate from the stomach wall too.

### **Histological and pathological findings**

#### *Histologic examination*

Histologically, tumor demonstrated combination of spindle cells, epithelioid cells, and scattered atypical polymorphous multinucleated cells. Neoplastic cells had pale cytoplasm with indistinct cells borders. Giant multinucleated cells contained in their cytoplasm small eosinophilic granules resembling autophagosomes. Nuclei tend to be uniform in the appearance, sometimes with atypical appearance and nuclear hyperchromasias. Stromal collagen was minimal and delicate, thin-walled vessels were present. Mitotic rate was increased; mitotic count was 1 per 50HPF (50 high power fields corresponding to 10 mm) (Figures 4, 5).

#### *Immunohistochemical examination*

The tumor cells stained strongly for vimentin and CD34. Antibody against synaptophysin weakly stained intracytoplasmic granules in some cells. S-100 protein, chromogranin, actin, CAM 5.2, AE1-3 and CD 117 c-kit were negative.

#### *Electron microscopy*

Ultrastructural examination was performed after formalin fixation, and tissue preservation was poor. But preserved neurosecretory granules were seen in the cytoplasm of some neoplastic cells. We were not able to identify interdigitating neurite-like cells processes and synapse-like clefts. Lack of myofilamentes with dense bodies excluded a smooth muscle origin. Schwann cells features, such as Luse bodies, and basal lamina were not found. Skenoid fibers were not identified.

### Postoperative period

Postoperative period was normal with healing of the wound per primam. The blood sugar levels were 6 – 7 mmol/l with a diabetic diet. The patient was discharged into home care on day 10 post surgery.

Due to the radical nature of the procedure, the patient has been followed up and clinically monitored on a regular basis. The schedule of monitoring includes CT control once every six months, and in the meantime control US examination of the abdomen. At the one-year postoperative follow-up visit, she was found to be free of subjective complaints, and the clinical findings were also normal; a CT scan showed no signs of recurring tumor.

### Discussion

Gastrointestinal stromal tumours (GISTs) are the most common gastrointestinal mesenchymal tumours, accounting for approximately 80% of these neoplasms. They may occur in the entire length of the gastrointestinal tract, from the esophagus to the anus. In the earlier literature, GISTs were designated as smooth muscle tumours. Now, GISTs are defined as cellular spindle cell, epitheloid, or occasionally pleomorphic mesenchymal tumours of the gastrointestinal tract that express the KIT. This definition specifically excludes gastrointestinal true smooth muscle tumors, and schwannomas and neurofibromas but includes gastrointestinal autonomic nerve tumors (GANT). [1]

Lesions that are morphologically and immunohistochemically indistinguishable from conventional GISTs have also been seen to occur in extragastrointestinal locations. The morphological diagnosis of GISTs appears to be relatively simple. The majority of cases can be in fact classified into three broad categories: spindle cell type, epitheloid type, and mixed spindle and epitheloid type. [1, 2]

It must be also recalled that approximately two-thirds of GISTs show immunopositivity for CD34, one-third for smooth muscle actin, and about 5% for S-100 protein, indicating a certain degree of immunophenotypic heterogeneity. GISTs are also typically strong positive for vimentin. All these markers are not specific for GISTs, they must be used in a panel with CD 117. The combination of CD 117 and CD 34 positivity has become a cornerstone in the diagnosis of GISTs. The majority of GISTs show KIT positivity in 90% of tumor cells, a small minority shows more focal staining of tumour cells. [3, 4] However, Sircar et al. showed loss of either CD 34 or c-kit positivity in their malignant GISTs. [5]

GISTs specific c-kit mutations were demonstrated in 50% of GANTs. Considering the indistinguishable patterns of c-kit mutations in GANTs and GISTs, these entities conceptually merge with regard to KIT molecular pathology. There is compelling evidence that GANT demonstrates clinicopathologic immunohistochemical, and molecular genetic identity with GIST. [6, 7] GANT is

a relatively recently described entity that is dependent of the varied histopathologic patterns shared by these tumors. The absence of myogenic, Schwannian, and epithelial features and the presence of neural differentiation are required to render a diagnosis of GANT. These tumors possess features of nerve plexus, including filopodia, interlacing neurites with dense core neurosecretory granules, and synapse like clefts. Several previously reported cases of GANT have demonstrated diffuse and intense staining for CD 34. Chromosomal analysis of GANT reveals no characteristic cytogenetic abnormalities and therefore electron microscopic definition of the ultrasctructural features is required for the unequivocal diagnosis of GANT. It is believed, that this tumor differentiates from gastrointestinal enteric plexus. [4, 8]

Our tumor was vimentin and CD 34 positive, c-kit negative. Its histological pattern was rather typical for malignant GISTs, because we observed increased mitotic rate and atypical giant cells with multiple nuclei. Electron microscopic examination proved the presence of small dense bodies of the neurosecretory granules type. On the basis of such findings we suppose that the tumor we refer is highly consistent with GIST showing some features of GANT. However, we were not able to identify all typical electron microscopic features of GANT. It may be the consequence of immaturity of this tumor having malignant character.

#### *Treatment*

Surgery is the basic method of treatment [9–12]. The purpose of the surgery is to achieve, where possible, a complete resection of the tumor. Possible perioperative rupture of the tumor capsule poses a risk of later dissemination, as tumors often have a cystic character [12]. The 5-year survival rate after the radical resection is 50 – 65%, while it is less than 35% in non-radical resection. The median of survival rate in non-resectable cases is 9 – 12 months [11–13].

Chemotherapy is ineffective in this type of tumor, as the response rate is less than 10%. In addition, GIST is radio-resistant, with less than 5% treatment response rate after radiotherapy. For these reasons, adjuvant therapy is not indicated after the radical surgery, as it provides no benefit before, at pre-, peri-, or post-operative rupture of the tumor capsule [12].

The only effective treatment of the advanced or metastatic disease is biological treatment with Imatinib (Glivec from Novartis) [14].

#### **Conclusion**

Presented Case report documents rare and yet unmapped occurrence of the gastrointestinal stromal tumor of the pancreas head and body. In comparison with indistinct conclusion of preoperative examinations and hardly predictable peroperative finding, it was later possible to histopathologically and immunohistochemically diagnose the tumor with high probability and to reveal

its clear signs of malignancy. Tumor was radically removed and after twelve months the patient has no signs of relapse of the disease. On the base of this case report there was performed an analysis of current knowledge of mentioned tumors.

## References

1. PROSS M., MANGER T., SCHULZ H. U., LIPPERT H., ROESSNER A., GUNTHER T.: Gastrointestinal stromal tumors-problems in diagnosis and therapy. *Chirurg*. 70: 807–812, 1999.
2. IRANI S., FARTAB M.: Gastrointestinaler stromatumor: ein chirurgisch-onkologisches sorgenkind? *Chirurg*. 70: 259, 1999.
3. FLETCHER C. D., BERMAN J. J., CORLES C., GORSTEIN F., LASOTA J. ET AL: Diagnosis of gastrointestinal stromal tumors: A consensus approach. *Human Pathology* 33: 459–466, 2002.
4. CHAN J. K.: Mesenchymal tumors of the gastrointestinal tract: A paradox for acronyms (STUMP, GIST, GANT and now GIPACT), implication of C-kit in genesis, and yet another of the many emerging roles of the intestinal cell of Cajal in the pathogenesis of gastrointestinal disease?. *Adv. Anat. Pathol.* 6: 19–40, 1999.
5. SIRCAR K., HEWLET B. R., HUIZINGA J. D., CHORNEYKO K., BEREZIN I., RIDDEL R.H.: Interstitial cells of Cajal as a precursors of gastrointestinal stromal tumors. *Am. J. Surg. Pathol.* 23: 377–389, 1999.
6. HIROTA S., ISOZAKI K., MORIYAMA Y., HASHIMOTO K.: Gain-of-function mutations of c-kit in human gastrointestinal stromal tumors. *Science* 279: 577–580, 1998.
7. LASOTA J., JASINSKI M., SARLOMO-RIKALA M. ET AL.: C-kit mutations occur preferentially in malignant vs. benign GISTs and do not occur in leiomyomas and leiomyosarcomas. *Am. J. Pathol.* 154: 53–60, 1999.
8. YASUOKA R., SAKARURA CH., SHIMOMURA K., FUJITA Y., NAKANISHI M., ARANGE H., HAGIWARA A., BAMBA M., ABE T., YAMAGISHI H.: Mutation in Exon 11 of the C-kit Gene in a myogenic tumor and a neurogenic tumor as well as in gastrointestinal stroma tumors. *Dig. Surg.* 20: 183–191, 2003.
9. MAŘATKA Z.: Gastroenterologie. Univerzita Karlova, Karolinum 1999; 190.
10. PIDHORECKY I., CHEJRY R. T., KRAYBILL W. G., GIBBS J. F.: Gastrointestinal stromal tumors: current diagnosis, biologic behavior, and management. *Ann. Surg. Oncol.* 7: 705–712, 2000.
11. DEMATTEO R. P., LEWIS J. J., LEJNY D., MUDAN S. S., WOODRUFF J. M., BRENNAN M. F.: Two hundred gastrointestinal stromal tumors: recurrence patterns and prognostic factors for survival. *Ann. Surg.* 231: 51–58, 2000.
12. DEMATTEO R., HEINRICH M. C., EL-RIFAI W. W., DEMETRI G.: Clinical management of gastrointestinal stromal tumors: Before and after STI-571. *Human Pathology* 33: 466–477, 2002.
13. PIERIE J. P., CHOUDRY U., MUZIKANSKY A., TRAP B. Y., SOUBA W. W., OTT M. J.: The effect of surgery and grade on outcome of gastrointestinal stromal tumors. *Arch. Surg.* 136: 383–389, 2001.
14. DEMETRI G. D. AND OTHERS: Efficacy and safety of Imatinib mesylate in advanced gastrointestinal stromal tumors. *N. Engl. J. Med.* 347: 472–480, 2002.