

Kainic Acid and Nitroergic Neurons in Immature Hippocampus

Jandová K., Riljak V., Pokorný J., Langmeier M.

Institute of Physiology of the First Faculty of Medicine, Charles University
in Prague, Czech Republic

Received November 23, 2006, Accepted December 12, 2006

Key Words: Kainic acid – Immature rats – Seizures – Cell degeneration –
NAPDH-diaphorase – Fluoro-Jade B

*This work was supported by grants GA ČR 305/03/H148,
GA ČR 309/05/2015, GA UK 45/2004 and MSM ČR 0021620816.*

Mailing Address: Kateřina Jandová, MD., PhD., Institute of Physiology,
First Faculty of Medicine, Albertov 5, 128 00 Prague 2, Czech Republic,
Phone: +420 224 968 443, Fax: +420 224 918 816,
e-mail: katerina.jandova@lf1.cuni.cz

Abstract: Using histochemical analysis the effect of intraperitoneal administration of kainic acid on hippocampal neurons was studied. 18-day-old male rats of the Wistar strain received kainic acid (10mg/kg) in one dose. Two days later, the 20-day-old animals were transcardially perfused with 4% paraformaldehyde under deep thiopental anaesthesia. Cryostat sections were stained to identify NADPH-diaphorase positive neurons that were then quantified in the CA1 and CA3 areas of the hippocampus, in the dorsal and ventral blades of the dentate gyrus and in the hilus of the dentate gyrus. Combination of the Fluoro-Jade B and bis-benzimide (Hoechst 33342) was used in the same areas, to identify possible neurodegeneration. After the kainic acid administration the number of NADPH-d positive neurons was lower in CA1 and CA3 areas of the hippocampus and in the hilus of the dentate gyrus, compared to the control group which we consider as baseline. Fluoro-Jade B staining detected a moderate density of neurodegeneration after KA administration in CA3 and CA1 areas of the hippocampus and the hilus of the dentate gyrus.

Introduction

Identification of causes and mechanism of neuronal damage is one of the most relevant problems in contemporary neuroscience and medicine [1].

Hyperexcitation and subsequent death of neurons underlies several brain diseases and most clearly is apparent in epilepsy [2, 3]. Among the experimental models of epilepsy, the most widespread are kainic acid (KA) induced seizures. This systemic convulsant agent is frequently used for screening antiepileptic drugs [4, 5, 6].

Excitotoxicity is a process by which the substances such as glutamate (in high concentration), kainic acid (KA), domoic acid etc. induce neuronal cell death in central nervous system [7]. This compounds cause in the CNS stimulation of ionotropic glutamate receptors, including the N-methyl-D-aspartate (NMDA), α -amino-3-hydroxy-5-methyl-4-isoxazole propionic acid (AMPA) and KA receptors [8, 9]. Excessive stimulation of these receptors leads to massive depolarization, drastically changes normal physiology of the neurons and may result in cell death by increasing intracellular Ca^{2+} and Na^+ [7, 10]. Neurodegeneration caused by systemic injection of KA has been widely used in experiments to investigate mechanisms of excitotoxicity and possible pharmacological intervention against the seizure events [11, 12]. Systemic injection of KA to rats is known to cause hippocampal damage. This damage is caused directly by stimulating KA receptors, indirectly by increasing the release of excitatory amino acids from nerve terminals [13, 14]. KA preferentially damages the pyramidal neurons of the CA3 area of the hippocampus, surviving neurons in the CA1 area of the hippocampus became hyperexcitable [10, 13, 14]. The molecular basis for this differential susceptibility is not completely clear. An important factor is a KA receptor level, which is very high in CA3 area of the hippocampus [15].

It has been proposed, that the main cause of KA-induced seizures and brain damage are: so called axon sparing lesions, lesions mediated through activation of excitatory pathways, non-selective seizure-related brain damage, changes in the blood-brain barrier [10]. The degenerating neurons display pathological features suggesting both necrosis and apoptosis [16, 17, 18, 19, 20, 21].

One of possible mechanism of brain injury is activation of some enzymes as nitric oxide synthases (NOS), resulting in nitric oxide (NO) production [22, 23]. NO is free radical that has several important biological functions. It acts as a vasodilator, as a toxic agent in inflammatory responses and as a neurotransmitter. NOS, enzyme responsible for the biosynthesis of NO from L-arginine, has at least three isoforms, the endothelial isoform (eNOS), which is membrane associated and was found in endothelial cells, the inducible isoform (iNOS) found predominantly in macrophages, and the neuronal isoform (nNOS) found in neurons of central and peripheral nervous system [24]. nNOS and eNOS are calmodulin dependent enzymes constitutively expressed in mammalian cells that generate increments of NO lasting a few minutes. The production must be preceded by the elevation of intracellular Ca^{2+} - concentration [25]. It has been observed that nNOS produces NO almost exclusively following activation of N-methyl-D-aspartate (NMDA) receptors [26].

In contrast, iNOS is Ca^{2+} -calmodulin independent and its regulation depends on de novo synthesis. iNOS is expressed following immunological or inflammatory stimulation in macrophages, astrocytes, microglia and other cells producing high amounts of NO lasting hours or days [27, 28].

Many studies have shown that NOS activity is co-localizes with neuronal nicotinamide adenine dinucleotide phosphate- diaphorase (NADPH-d) catalytic activity and it is therefore suggested that neurons containing NADPH-d might be capable of producing NO [29, 30].

The aim of this experiment was to observe the morphological changes in the hippocampus after systemic KA administration in convulsive dose and to describe and compare the postnatal development of NOS activity (using histochemical method NADPH-diaphorase staining) in immature hippocampus (20-day-old rats) as well as the modifications on the nitrergic system after application of this excitotoxic substance, during a period of structural and functional maturation of the CNS.

To evaluate histological changes bis-benzimide (Hoechst 33342) and Fluro-Jade B dye were used.

Materials and Methods

Male rats 18-day-old of the Wistar strain of our own breed were used for the experiments. They were housed at a constant temperature (23°C) and relative humidity (60%) with a fixed 12 hr light/dark cycle and fed with food and water *ad libitum*. Procedures involving animals and their care were conducted in conformity

with the institutional guidelines that are in compliance with national and international laws and policies. There were 12 animals in all the experimental groups, six animals in each group:

- 1) 18-day-old animals received corresponding volumes of normal saline solution i.p.
- 2) 18-day-old animals received one dose of kainic acid (10 mg/kg) i.p.

For our experiment only the animals, which had elicited the tonic-clonic seizures, were used. Four brains of animals in each group were stained by NADPH-diaphorase method and 2 brains in each group were stained by combination of Fluoro-Jade B and Hoechst staining. In each brain 25–30 sections were examined or quantified. Animals were studied the 20th day, two days after the drug administration. All rat pups were perfused under deep thiopental anaesthesia with 4% paraformaldehyde in 0.1M phosphate buffer at pH 7.4. Brains were removed, postfixed for one hour in 4% buffered paraformaldehyde and then submerged for 1 h into 20 % sucrose for cryoprotection. Each brain was sliced in the frontal plane into 40 μ m thick sections with a cryostat. Than two different histochemical methods were used:

1) *NADPH-diaphorase staining*

For the NADPH-diaphorase examination the free-floating sections were placed in 0.1 M phosphate buffer and incubated in 0.1 M phosphate buffer containing 0.5 mg/ml β -NADPH (Sigma), 0.2 mg/ml Nitro blue tetrazolium (NBT, Sigma) and 0.3 % Triton (Sigma) for 4 h at 37 °C in thermostat. Following the reaction, sections were rinsed in 0.1 M phosphate buffer and kept at 8 °C for 16 h. The histochemically reacted sections were mounted on precleaned 0.5 % gelatine-coated microscope slides (Menzel-Gläser), air-dried and cover slipped with microscope cover glasses (Menzel-Gläser) using D. P. X. neutral mounting medium (Aldrich) [31]. NADPH-d positive neurons were then quantified in five regions of the hippocampal formation (each section was taken and evaluated) (Colour Figures 1, 2):

- 1) In CA1 area of the hippocampus,
- 2) In CA3 area of the hippocampus,
- 3) In the hilus of the dentate gyrus,
- 4) In the dorsal blade of the dentate gyrus,
- 5) In the ventral blade of the dentate gyrus

Hippocampus in brain slices, which were acquired between the AP plane 2.5 mm and 4.0 mm posterior to the bregma was subjected to quantification of NADPH-d positive neurons under the light microscope Olympus Provis AX 70 with epifluorescence. For the statistical evaluation, ANOVA and the unpaired t-test (GraphPadPrism) were used (level of significance was set at $p < 0.05$).

2) Combination of the Fluoro-Jade B (Histo-Chem Inc.) and bis-benzimide 33342 Hoechst (Sigma)

Fluoro-Jade B (FJB) is an anionic fluorescein derivative useful for the histological staining of neurons undergoing degeneration [33]. Hoechst 33342 staining was used as an apoptotic marker, which detects apoptotic nuclei with condensed and/or fragmented DNA.

After cryostat sectioning free-floating slices were placed in 0.1 M phosphate buffer. Tissue sections were then mounted onto gelatinized slides and allowed to dry at room temperature. Slides were then placed in staining racks (one slide/slot for even staining) and immersed in 100% ethanol solution for 3 minutes, in 70% ethanol solution for 1 minute, in distilled water for 1 minute, in 0.01% potassium permanganate (KMnO₄) (Sigma) for 15 minutes with gentle shaking. Slides were washed in distilled water three times. Staining proceeded in dim place by

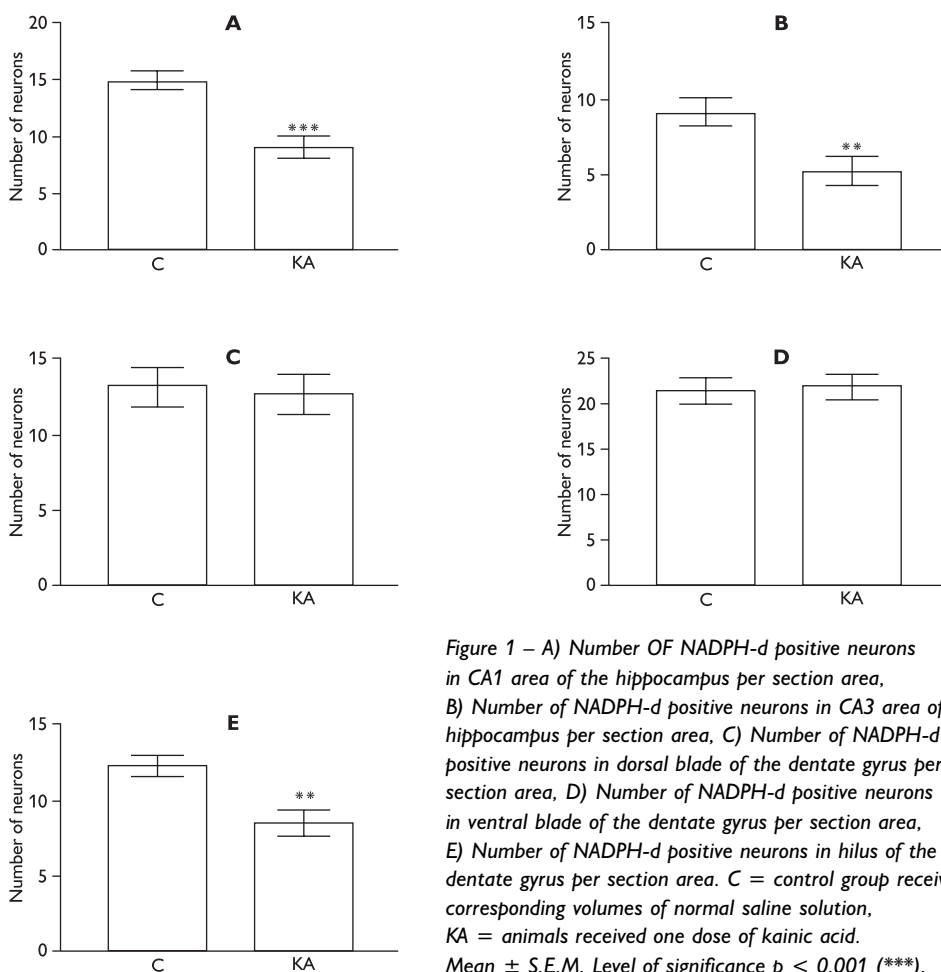


Figure 1 – A) Number OF NADPH-d positive neurons in CA1 area of the hippocampus per section area, B) Number of NADPH-d positive neurons in CA3 area of hippocampus per section area, C) Number of NADPH-d positive neurons in dorsal blade of the dentate gyrus per section area, D) Number of NADPH-d positive neurons in ventral blade of the dentate gyrus per section area, E) Number of NADPH-d positive neurons in hilus of the dentate gyrus per section area. C = control group received corresponding volumes of normal saline solution, KA = animals received one dose of kainic acid. Mean \pm S.E.M. Level of significance $p < 0.001$ (***).

immersing slides into 0.001% Fluoro-Jade B solution for 30 minutes with occasional gentle shaking [32]. After that slides were rinsed in the distilled water three times for 1 minute. Slides were then immersed in 0.01% Hoechst staining solution for 10 minutes and dehydrated (in ethanol series); cover-slipped using D. P. X. neutral mounting medium and allowed to dry. Fluoro-Jade B positive neurons were studied in the same hippocampal regions as those used for NADPH-d evaluation (each section was taken and evaluated). The tissue was examined using an epifluorescent microscope with blue (450–490 nm) excitation light. Semiquantitative analyze of Fluoro-Jade B (FJB) positive cells were examined by two independent experimentators in all slices. Each area of the hippocampus in the slice was evaluated by the scale: (0) no FJB positive cells in field of view, (+) sporadically present FJB cells in field of view, (++) groups of FJB positive cells in field of view (+++) massive alteration, the study area is completely undergoing degeneration.

Results

Kainic acid administration reduced the number of NADPH-d positive neurons in CA1 area of the hippocampus by 39% ($p < 0.001$), in CA3 area by 43% ($p < 0.01$) and in the hilus of the dentate gyrus by 31% ($p < 0.01$), changes in number of NADPH-d positive cells in the ventral and dorsal blades of the dentate gyrus were not significant, compared to the control group which we consider as baseline (Figure 1).

Semiquantitative analysis of Fluoro-Jade B staining elucidated the neurodegeneration after KA application. The most affected regions were CA3 and CA1 areas of the hippocampus and hilus of the dentate gyrus. Both blades of the dentate gyrus remained intact (Table 1, Colour Figures 3A, 4A, 5A). Morphological analysis, using Hoechst 33342, confirmed, that KA administration caused neuronal morphological changes (condensed nuclei, apoptotic bodies), reflecting of apoptosis in the pyramidal layer of the hippocampal formation (Colour Figures 3B, 4B, 5B).

Table 1 – Semiquantitative analyze of Fluoro-Jade B positive cells in experimental groups

Area	Exp. Group	
	Control	KA
CA1	0	+
CA3	0	+/++
Hilus	0	+/++
VB DG	0	0/+
DB DG	0	0/+

Control – control group received equal dose of normal saline solution, KA – kainic acid treated rats (10mg/kg). Each area of the hippocampus in the slice was evaluated by the scale: (0) no FJB positive cells in field of view, (+) sporadically present FJB cells in field of view, (++) groups of FJB positive cells in field of view (+++) massive alteration, the study area is completely undergoing degeneration.

Discussion

Human epilepsy in infants and children and prolonged seizures in the early developmental period can cause brain damage and lead to serious consequences later in life. 18-day-old (perfused as 20-day-old) rats were chosen because of the level of brain maturation which is comparable to the postnatal period in human infants [35].

In the present study, we tried to identify morphological changes of immature brain after KA administration. It is well known that this substance causes epileptic seizures and brain damage, acting on various receptors groups and it is well established that the consequences of status epilepticus in the developing brain differ from those of the mature brain [33, 34, 36, 37, 38].

Systemic administration of the KA in the rats readily produces various motor signs including convulsive seizures [11] and massive neuronal damage can be observed in the hippocampal formation [15, 39]. It was confirmed in our experiment showing that intraperitoneal administration of KA brought about death of neurons in the CA1 and CA3 areas of the hippocampus and in the hilus of the dentate gyrus. Mechanisms contributing to KA-induced seizures and brain damage are still not completely clear. The main causes are: so called axon sparing lesions, lesions mediated through activation of excitatory pathways, non-selective seizure-related brain damage, changes in the blood-brain barrier and possibly some other [15]. One cause of the high sensitivity of CA1 and CA3 areas of the hippocampus can be the high concentration of KA receptors upon the neurons in this structure [40, 41].

The character of neuronal injury is concerned, two major forms of morphologically distinct cell death have been observed under various neuropathologic conditions: necrosis and apoptosis [42, 43]. Frequently it is difficult to decide whether the cell died by the necrotic or apoptotic process [44]. The mechanism of neuronal death in the hippocampus, demonstrated in our experiments, is most likely apoptotic. But without any other histological method the necrotic process in the hippocampus cannot be excluded.

Although the threshold for seizure generation is lower in immature brains than adult brains, developing neurons are less vulnerable, in terms of neuronal damage and cell loss, than adult neurons to a wide variety of pathologic insults [45].

One of the reasons that the immature brain is resistant to cell loss from prolonged seizures is that glutamate is less toxic to the immature brain relative to the mature brain [46, 47, 48].

Increases in intracellular Ca^{2+} caused severe swelling of the cell and retraction of dendrites into the soma, and Marks and collaborators found that the degree of Ca^{2+} entry into the hippocampal subfield CA1 and subsequent damage was directly related to age [48].

As well as the hippocampal lesions were highly age-dependent, in study by Liu et al. where glutamate were administered in equal amounts unilaterally into the CA1

subfield of the hippocampus of rats at postnatal (P) days 10, 20, 30, and 60. Rats were killed 7 days later. The size of the resultant hippocampal lesion was highly age-dependent. Minimal cell loss was observed in the P10 rats, lesions in the P20 rats were smaller than those at P30 and P60, which were similar in extent [47].

This relative resistance of immature brain is thought to be due to the smaller density of active synapses, lower energy consumption, and in general, the relative immaturity of biochemical cascades that lead to cell death following insults [45].

In our experiments, kainic acid administration decreased the number of the NADPH-positive neurons. It can result from kainic acid induced neurodegeneration in the hippocampal area, or it is a consequence of kainic acid application that decreases the number of all neurons and the NADPH-diaphorase positive neurons are not excluded. It has been proposed that some other insults (for example perinatal long-lasting hypobaric hypoxia) result in decrease number of NADPH-d positive neurons [49, 50, 51]. Considering, that in our experiment the dose of kainic acid reached the convulsive limit, the cell loss was not surprising. Some authors, who studied effects of subconvulsive doses of the kainic acid, did not find any structural changes in the hippocampus [52]. These findings are in line with our previous experiments where KA was administered to older (35-day old) animals. These experiments elicited that i.p. KA application significantly decreased the number of NADPH-d positive cells in CA1, CA3 areas of the hippocampus and in the hilus of the dentate gyrus [60]. It seems very likely that the nitrergic neurons system reacts similar in different level of brain maturation.

In the literature it is well documented that the CA3 area of the hippocampus is most likely the most vulnerable structure of the hippocampal formation [8, 9, 15] (also this finding was not surprising) and epileptiform activity propagates from this area to CA1 area of the hippocampus via Schaeffer's collaterals. Some investigators [15, 39] speculated that the selective destruction of CA3 area of the hippocampus may paradoxically protect the area CA1. This hypothesis was sustained by our previous experiments where the kainic acid has been applied more than once. The results showed that subconvulsive dose of this compound, applied six times, selectively extinct pyramidal cells of CA3 area of the hippocampus while neurons in CA1 area remained practically intact [39].

In this experiment the kainic acid administration the number of NADPH-diaphorase positive neurons in CA3 and CA1 areas of the hippocampus and hilus of the dentate gyrus in the comparison with either group of control animals in rats was decreased. NADPH-d positive neurons were repeatedly reported to be relatively resistant to the injury caused by status epilepticus [53, 54], however, the findings related to vulnerability or this neuronal population survival after status epilepticus are still controversial. As well as the role of nitrergic system remains unclear in the central nervous system. NO is likely to play an important role as a mediator of excitotoxic neuronal injury, it is important to determine the NOS activity during development and establish whether this expression predicts

the areas of the brain that are vulnerable to injury from excitotoxic insults. NOS is the only enzyme with NADPH – diaphorase activity in formaldehyde fixed tissue, and so this histochemical procedure can be used to identify NOS-containing cells [29]. NADPH-d reactivity was detected in various regions of the nervous system of mammals including the rat. The coexistence of NADPH-d reactivity and neurotransmitter or neuropeptide reactivity was demonstrated in several neuronal populations [31].

It should be noted that nitric oxide is a critical mediator and modulator of neuronal injury as evidenced by the administration of pharmacological inhibitors of NOS that reduce neuronal injury from focal ischemia, NMDA-dependent excitotoxicity and cerebral hypoxia [55, 56, 57, 58] .

The exact borderline between physiological, and therefore neuroprotective, and pathological, and therefore neurodegenerative, actions of NO is a matter of controversy among researchers in the field. This is reflected in the present status of drug research that is focused on finding ways to block NO production, and therefore limit neuropathology, as well as on finding ways to increase NO availability and therefore elicit neuroprotection [59].

References

1. SLOVITER R. S.: "Epileptic" brain damage in rats induced by sustained electrical stimulation of the perforant path. Acute electrophysiological and light microscopic studies. *Brain Res. Bull.* 10: 675–697, 1983.
2. MCINTYRE D. C., NATHARISON D., EDSON N.: A new model of partial status epilepticus based on kindling. *Brain Res.* 250: 53–63, 1982.
3. COLLINS R. C., OLNEY J. W.: Focal cortical seizures cause distant thalamic lesions. *Science* 218: 177–179, 1982.
4. BEN-ARI Y., TREMBLAY E., RICHE D., GHILINI G., NAQUET R.: Electrographic, clinical and pathological alterations following systemic administration of kainic acid, bicuculline and pentetrazole: metabolic mapping using the deoxyglucose method with special reference to the pathology of epilepsy. *Neuroscience* 6: 1361–1391, 1981.
5. MELDRUM B.: Excitotoxicity and epileptic brain damage. *Epilepsy Res.* 10: 55–61, 1991.
6. KÖHLER C., SCHWARCZ R., FUXE K.: Hippocampal lesions indicate differences between excitotoxic properties of acidic amino acids. *Neurosci Lett.* 175: 366–371, 1979.
7. SPERK G., LASSMANN H., BARAN H., KISH S. J., SEITELBERGER F., HORNYKIEWICZ O.: Kainic acid induced seizures: Neurochemical and histopathological changes. *Neuroscience* 10: 1301–1315, 1983.
8. BEN-ARI Y., TREMBLAY E., OTTERSEN O. P.: Injections of kainic acid into the amygdaloid complex of the rat: an electrographic, clinical and histological study in relation to the pathology of epilepsy. *Neuroscience* 5: 515–528, 1980a.
9. BEN-ARI Y., TREMBLAY E., OTTERSEN O. P., MELDRUM B. S.: The role of epileptic activity in hippocampal and "remote" cerebral lesions induced by kainic acid. *Brain Res.* 191: 79–97, 1980b.
10. SCHWOB J. E., FULLER T., PRICE J., OLNEY J. W.: Widespread patterns of neuronal damage following systemic or intracerebral injection of kainic acid: a histological study. *Neuroscience* 5: 991–1014, 1980.

11. BEN ARI Y.: Limbic seizure and brain damage produced by kainic acid: mechanism and relevance to human temporal lobe epilepsy. *Neuroscience* 14: 375–403, 1985.
12. TANAKA T., TANAKA S., FUJITA T., TAKANO K., FUKUDA H., SAKO K., YONEMASU Y.: Experimental complex partial seizures induced by a microinjection of kainic acid into limbic structures. *Prog. Neurobiol.* 38: 317–334, 1992.
13. TAUCK D. L., NADLER J. V.: Evidence of functional mossy fiber sprouting in hippocampal formation of kainic acid-treated rats. *J. Neurosci.* 5: 1016–1022, 1985.
14. PHELPS S., MITCHELL J., WHEAL H. W.: Changes to synaptic ultrastructure in field CA1 of the rat hippocampus following intracerebroventricular injection of kainic acid. *Neuroscience* 40: 687–699, 1991.
15. SPERK G.: Kainic acid seizures in the rat. *Prog. Neurobiol.* 42: 1–32, 1994.
16. MCGEER E. G., OLNEY J. W., MCGEER P. L.: Kainic acid as a tool in neurobiology. Raven Press, New York, 1978.
17. KÖHLER C., SCHWARCZ R.: Comparison of ibotenate and kainate neurotoxicity in rat brain: a histological study. *Neuroscience* 8: 819–835, 1983.
18. UNNERSTALL J. R., WAMSLEY J. K.: Autoradiographic localisation of high-affinity [3H]kainic acid binding sites in the rat forebrain. *Eur. J. Pharmac.* 86: 361–371, 1983.
19. ZACZEK R., SCHWARCZ R., COYLE J. T.: Long-term sequelae of striatal kainate lesion. *Brain Res.* 152: 626–632, 1978.
20. OKAZAKI M.M., NADLER J.V.: Protective effects of mossy fiber lesions against kainic acid induced seizures and neuronal degeneration. *Neuroscience* 26: 763–781, 1988.
21. BEN-ARI Y., TREMBLAY E., OTTERSEN O. P., NAQUET R.: Evidence suggesting secondary epileptogenic lesions after kainic acid : pre-treatment with diazepam reduces distant but not local damage. *Brain Res.* 165: 362–365, 1979.
22. BERGER R., GARNIER Y.: Pathophysiology of perinatal brain damage. *Brain Res. Brain Res. Rev.* 30: 107–134, 1999.
23. LEE J. M., GRABB M. C., ZIPFEL G. J., CHOI D. W.: Brain tissue responses to ischemia. *J. Clin. Invest.* 106: 723–731, 2000.
24. BLACK S. M., BEDOLLI M. A., MARTINEZ M. A., MARTINEZ M. A., BRISTOW J. D., FERRIERO D. M., SOIFER S. J.: Expression of neuronal nitric oxide synthase corresponds to regions of selective vulnerability to hypoxia-ischaemia in the developing rat brain. *Neurobiol. Dis.* 2: 145–155, 1995.
25. KISS J. P.: Role of nitric oxide in the regulation of monoaminergic neurotransmission. *Brain Res. Bull.* 52: 459–466, 2000.
26. GARTHWAITE J., BOULTON C. L.: Nitric oxide signaling in the central nervous system. *Annu. Rev. Physiol.* 57: 683–706, 1995.
27. GUIX F. X., URIBESALGO I., COMA M., MUNOZ F. J.: The physiology and pathophysiology of nitric oxide in the brain. *Prog. Neurobiol.* 76: 126–152, 2005.
28. IADECOLA C., ZHANG F., XU S., CASEY R., ROSS M. E.: Inducible nitric oxide synthase gene expression in brain following cerebral ischemia. *J. Cereb. Blood Flow Metab.* 15: 378–384, 1995.
29. HOPE B. T., MICHAEL G. J., KNIGGE K. M., VINCENT S. R.: Neuronal NADPH diaphorase is a nitric oxide synthase. *Proc. Natl. Acad. Sci. USA* 88: 2811–2814, 1991.
30. FLESCH I. E., HESS J. H., KAUFMANN S. H.: NADPH diaphorase staining suggests a transient and localized contribution of nitric oxide to host defence against an intracellular pathogen in situ. *Int. Immunol.* 6: 1751–1757, 1994.
31. WANG T. J., LUE J. H., SHIEH J. Y., WEN C. Y.: The distribution and characterization of NADPH-d/NOS-IR neurons in the rat cuneate nucleus. *Brain Res.* 910: 38–48, 2001.

32. SCHMUED L. C., HOPKINS K. J.: Fluoro-Jade B: a high affinity fluorescent marker for the localization of neuronal degeneration. *Brain Res.* 874: 123–130, 2000.
33. FRENCH E. D., ALDINIO C., SCHWARCZ R.: Intrahippocampal kainic acid, seizures and local neuronal degeneration: relationships assessed in unanesthetized rats. *Neuroscience* 7: 2525–2536, 1982.
34. DE MONTIGNY C., TARDIF D.: Differential excitatory effects of kainic acid on CA3 and CA1 hippocampal pyramidal neurons: further evidence for the excitotoxic hypothesis and for a receptor-mediated action. *Life Sci.* 29: 2103–2111, 1981.
35. DOBBING J.: Undernutrition and the developing brain. In: *Developmental neurobiology* HIMWICH W. A., THOMAS C. C. (eds) Springfield, 1970, 241–261.
36. OLNEY J. W., FULLER T., DE GUBAREFF T.: Acute dendrotoxic changes in the hippocampus of kainate-treated rats. *Brain Res.* 176: 91–100, 1979.
37. LOTHMAN E. W., COLLINS R. C.: Kainic acid induced limbic seizures: metabolic, behavioral, electroencephalographic and neuropathological correlates. *Brain Res.* 218: 299–318, 1981.
38. BLENNOW G., BRIERLEY J. B., MELDRUM B. S., SIESJÖ B. K.: Epileptic brain damage. The role of systemic factors that modify cerebral energy metabolism. *Brain* 101: 687–700, 1978.
39. RILJAK V., MILOTOVÁ M., JANDOVÁ K., LANGMEIER M., MAREŠOVÁ D., POKORNÝ J., TROJAN S.: Repeated kainic acid administration and hippocampal neuronal degeneration. *Prague Med. Rep.* 106: 75–78, 2005.
40. SAWADA S., HIGASHIMA M., YAMAMOTO C.: Kainic acid induces long-lasting depolarizations in hippocampal neurons only when applied to stratum lucidum. *Exp. Brain Res.* 72: 135–140, 1988.
41. YOSHIHARA Y., ONODERA H., IINUMA K., ITOYAMA Y.: Abnormal kainic acid receptor density and reduced seizure susceptibility in dystrophin-deficient mdx mice. *Neuroscience* 117: 391–395, 2003.
42. JOHNSON E. M., DECKWERTH T. L.: Molecular mechanism of developmental neuronal death. *Annu. Rev. Neurosci.* 16: 31–46, 1993.
43. NICOTERA R., LIPTON S. A.: Excitotoxins in neuronal apoptosis and necrosis. *J. Cereb. Blood Flow Metab.* 19: 583–591, 1999.
44. COLUMBANO A.: Cell death: current difficulties in discriminating apoptosis from necrosis in the context of pathological processes in vivo. *J. Cell Biochem.* 58: 181–190, 1995.
45. HOLMES G. L.: Effects of seizures on brain development: lessons from the laboratory. *Pediatr. Neurol.* 33: 1–11, 2005.
46. BICKLER P. E., GALLEGOS S. M., HANSEN B. M.: Developmental changes in intracellular calcium regulation in rat cerebral cortex during hypoxia. *J. Cereb. Blood Flow Metab.* 13: 811–819, 1993.
47. LIU Z., STAFSTROM C. E., SARKISIAN M., TANDON P., YANG Y., HORI A., HOLMES G. L.: Age-dependent effects of glutamate toxicity in the hippocampus. *Brain Res. Dev. Brain Res.* 97: 178–184, 1996.
48. MARKS J. D., FRIEDMAN J. E., HADDAD G. G.: Vulnerability of CA1 neurons to glutamate is developmentally regulated. *Dev. Brain Res.* 97: 194–206, 1996.
49. BENEŠOVÁ P., LANGMEIER M., BETKA J., TROJAN S.: Long-lasting changes in the density of nitrergic neurons following kainic acid administration and chronic hypoxia. *Physiol. Res.* 54: 565–571, 2005.
50. MAREŠOVÁ D., JANDOVÁ K., BORTELOVÁ J., TROJAN S., TRNKOVÁ B.: Functional and morphological changes of the brain in rats exposed to intermittent hypobaric hypoxia after the repetitive magnesium administration. *Prague Med. Rep.* 106: 61–69, 2005.
51. JANDOVÁ K., LANGMEIER M., MAREŠOVÁ D., POKORNÝ J., TROJAN S.: Effect of magnesium pre-treatment on the hippocampal NOS activity during long-lasting intermittent hypoxia. *Prague Med. Rep.* 107: 108–116, 2006.

52. KORYNTOVA H., SLAPAL R., LANGMEIER M., HAUGVICOVA R., MARES P.: Effects of a subconvulsant dose of kainic acid on afterdischarges elicited by cortical stimulation in rats. *Epilepsy Res.* 29: 25–33, 1997.
53. KOH J. Y., PETERS S., CHOI D. W.: Neurons containing NADPH-diaphorase are selectively resistant to quinolinate toxicity. *Science* 234: 73–76, 1986.
54. LERNER-NATOLI M., DE BOCK F., BOCKAERT J., RONDOUIN G.: NADPH diaphorase-positive cells in the brain after status epilepticus. *Neuroreport* 5: 2633–2637, 1994.
55. BOLANOS J. P., ALMEIDA A., STEWART V., PEUCHEN S., LAND J. M., CLARK J. B., HEALES S. J.: Nitric oxide-mediated mitochondrial damage in the brain: mechanisms and implications for neurodegenerative diseases. *J. Neurochem.* 68: 2227–2240, 1997.
56. HUANG Z., HUANG P. L., PANATHIAN N., DALKARA T., FISHMAN M. C., MOSKOWITZ M. A.: Effects of cerebral ischemia in mice deficient in neuronal nitric oxide synthase. *Science* 265: 1183–1185, 1994.
57. YUN H. Y., DAWSON V. L., DAWSON T. M.: Nitric oxide in health and diseases of the nervous system. *Mol. Psychiatry* 2: 300–310, 1997.
58. NUMAGAMI Y., ZUBROW A. B., MISHRA O. P., DELIVORIA-PAPADOPOULOS M.: Lipid free radical generation and brain cell membrane alteration following nitric oxide synthase inhibition during cerebral hypoxia in the newborn piglet. *J. Neurochem.* 69: 1542–1547, 1997.
59. CONTESTABILE A., MONTI B., CONTESTABILE A., CIANI E.: Brain nitric oxide and its dual role in neurodegeneration/neuroprotection: understanding molecular mechanisms to devise drug approaches. *Curr. Med. Chem.* 10: 2147–2174, 2003.
60. RILJAK V., MILOTOVÁ M., JANDOVÁ K., POKORNÝ J., LANGMEIER M.: Morphological Changes in the Hippocampus Following Nicotine and Kainic Acid Administration. *Phys. Res.* 58: 000–000, 2008. (in press)